

Squamous Cell Carcinoma Tumor Seeding after Percutaneous Biopsy: A Rare Complication

Michael Leshen, Andrew Cantos

Department of Imaging Sciences, University of Rochester Medical Center, 610 Elmwood Drive, Rochester, New York, United States



Corresponding Author:

Michael Leshen, Department of Imaging Sciences, University of Rochester Medical Center, 601 Elmwood Ave, Box 648, Rochester, New York, 14642, United States. Email: michael_leshen@urmc.rochester.edu

ABSTRACT

Tumor seeding following percutaneous biopsy is an exceedingly rare complication. We present a case of a 65-year-old male with metastatic squamous cell carcinoma, likely of pulmonary origin, who developed paraspinal musculature and liver metastasis after adrenal mass biopsy.

Keywords: Biopsy, Squamous cell carcinoma, Tumor seeding

AJIR

Received: 21 December 2018

Accepted: 13 January 2019

Published: 29 January 2019

INTRODUCTION

Percutaneous needle biopsy has been a common diagnostic tool since the 1940s, and even then, there were concerns regarding needle tract seeding after oncologic tissue biopsy.^[1] Several papers have attempted to determine the true incidence. However, it is an exceedingly rare event and many of these papers do not provide an adequate sample size to detect a single event.^[2] We report a case of paraspinal muscle tract and liver seeding after an adrenal gland lesion biopsy in a patient with known squamous cell carcinoma of the lung.

CASE REPORT

A 65-year-old male with a reported history of malignant melanoma presented with a painful, enlarging neck mass. A fine-needle aspiration (FNA) of the mass was non-diagnostic and laryngoscopy was unremarkable. A follow-up excisional biopsy of the mass demonstrated metastatic carcinoma, favoring squamous cell carcinoma. However, the majority of the sample was necrotic tissue, which limited further characterization. A positron emission tomography (PET)/computed tomography (CT) demonstrated PET-avid lesions including a right level IV neck mass (SUV 17) and bilateral hilar lymph nodes (SUV 4.4 and 5.0). In addition, there was a 1.7 cm right adrenal lesion with an SUV 11.8 (Figure 1).

Subsequently, the patient underwent biopsies of multiple PET-avid lesions. An endoscopic bronchial ultrasound of the hilar lymph nodes was negative. A 19-gauge coaxial needle and a 20-gauge Monopty core biopsy gun (Bard Biopsy, Tempe, Arizona, USA) were used to biopsy the

Access this article online

Quick Response Code:



Website:
www.americanjir.com

DOI:
10.25259/AJIR-54-2018

This is an open-access article distributed under the terms of the Creative Commons Attribution-Non Commercial-Share Alike 4.0 License, which allows others to remix, tweak, and build upon the work non-commercially, as long as the author is credited and the new creations are licensed under the identical terms.

right adrenal gland under CT guidance (Figure 2). Three core tissue samples were obtained. The right neck mass also underwent fine-needle aspirate. Pathology demonstrated poorly differentiated squamous cell carcinoma. Due to high expressions of programmed death-ligand 1, the primary tumor was thought to be of lung origin. The patient began radiation for his painful neck mass and pembrolizumab.

Despite therapy, the patient continued to have worsening back and flank pain. 2 months after the right adrenal lesion biopsy, a repeat PET/CT demonstrated significant progression of disease including new osseous metastasis, peritoneal carcinomatosis, and innumerable liver lesions. In addition, there was significant PET avidity along the prior adrenal biopsy tract and in the right paraspinal muscles with an SUV of 22 (Figure 3).

Approximately 1 week later, the right paraspinal muscle lesion was biopsied under ultrasound guidance (Figure 4) using an 18-gauge Temno Evolution biopsy gun (Becton,

Dickinson and Company, Franklin Lakes, New Jersey, USA). Three core samples were obtained. The results were consistent with poorly differentiated squamous cell carcinoma.

DISCUSSION

Many disease processes require tissue diagnosis before appropriate treatment. Conventionally, tissue was acquired through incisional or excisional biopsy. An incisional biopsy results in removal of a portion of the lesion for testing,

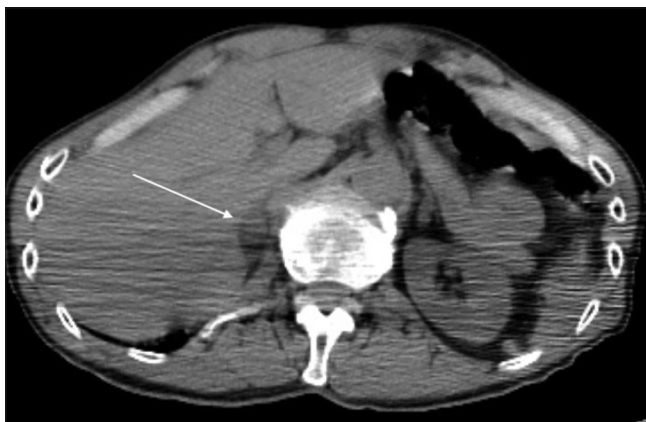

Figure 1: A 65-year-old male with metastatic squamous cell carcinoma. Axial non-contrast-enhanced computed tomography demonstrates a soft tissue lesion in the right adrenal gland (white arrow)

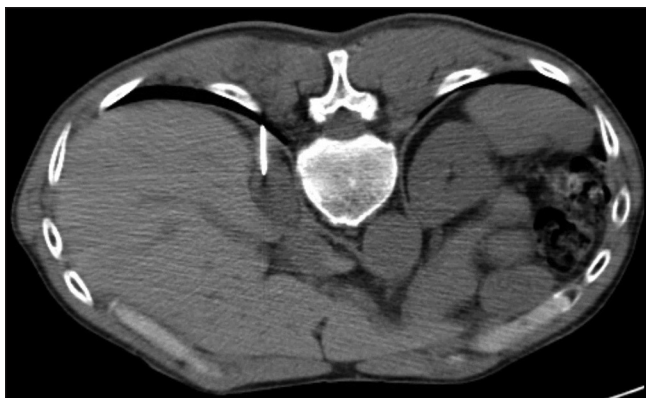

Figure 2: A 65-year-old male with metastatic squamous cell carcinoma. Axial non-contrast-enhanced computed tomography demonstrates a biopsy needle within the right adrenal lesion

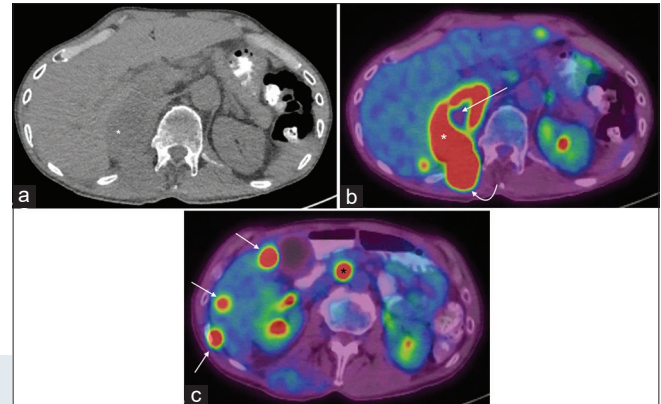


Figure 3: A 65-year-old male with metastatic squamous cell carcinoma. (a) Axial non-contrast-enhanced computed tomography (CT) demonstrates a significant increase in the right adrenal soft tissue lesion (white asterisk). (b) Axial fusion positron emission tomography (PET)/CT demonstrates a hypermetabolic right adrenal lesion (white asterisks) with a necrotic center (straight white arrow). There is an additional hypermetabolic soft tissue nodule in the right paraspinal muscles (curved white arrow), which is contiguous with the hypermetabolic right adrenal lesion. (c) Axial fusion PET/CT demonstrates numerous hypermetabolic hepatic metastases (white arrows). There is an additional enlarged, hypermetabolic para-aortic lymph node (black asterisk)

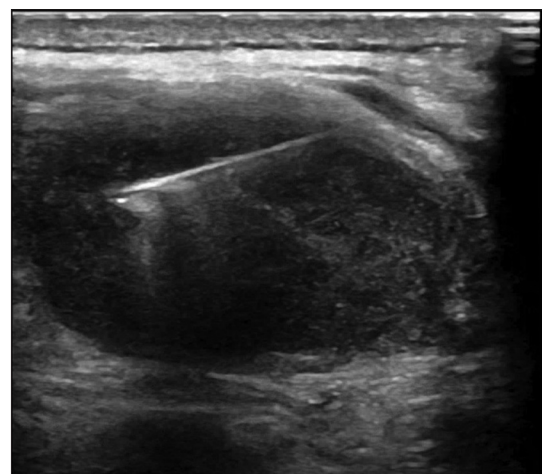


Figure 4: A 65-year-old male with metastatic squamous cell carcinoma. An ultrasound demonstrates a biopsy needle within a hypoechoic right paraspinal lesion

whereas an excisional biopsy results in complete removal of the lesion. More recently, image-guided needle biopsy has become the standard. In general, these are performed under ultrasound, fluoroscopy, or CT guidance. Less frequently, they are performed under magnetic resonance guidance.

The Society of Interventional Radiology Standards of Practice Committee has classified image-guided percutaneous biopsy complications into two categories: Major and minor. Major complications result in an unplanned hospital admission, unplanned increase in level of care, prolonged hospitalization, permanent adverse sequelae, or death. Minor complications result in a short hospitalization for observation or minimal treatment.^[3] Common complications include bleeding, infection, unintentional organ injury, and various organ-specific complications (such as pneumothorax).

One rare, but feared, major complication of an oncologic tissue biopsy is tumor seeding. The majority of literature regarding tract seeding is case based and includes multiple solid organ tumors including sarcoma, gastrointestinal, urologic, respiratory, breast, and thyroid. Some literature reviews have attempted to estimate the incidence of tract seeding of specific tumors. For example, Silva *et al.* estimated the risk of tract seeding of up to 2.7% following hepatocellular carcinoma biopsy.^[4] Systematic reviews of tract seeding following thyroid and prostate biopsies have demonstrated a much lower incidence, <1%.^[5,6] In 1976, Sinner and Zajicek found an incidence of 0.02% for patients who underwent transthoracic percutaneous needle biopsy for pulmonary malignancy.^[7] It has been suggested that the incidence of pulmonary biopsy tract seeding is increased in adenocarcinoma and with larger cutting needles.^[8]

There are multiple confounding factors when trying to determine the true incidence of tumor seeding after biopsy. In many cases, it may be impossible to discriminate between clinically and radiologically occult metastatic disease versus tumor seeding. In addition, many patients undergo treatment shortly after their biopsy results are finalized. When comparing our patients post-biopsy clinical and imaging findings, it was fairly apparent that the new right paraspinal lesion was in the exact path of the right adrenal biopsy.

Unfortunately, there is no clinically proven way to prevent biopsy tract seeding from tumor cells for routine biopsies. Mu *et al.* described a two-step freezing method with the use of percutaneous cryoablation after biopsy, but before needle removal, which demonstrated necrotic tissue along the biopsy tract after surgical resection.^[9] However, this was only performed in one patient and no clinical trials have evaluated the technique.

Several studies have attempted to evaluate biopsy techniques variations and tumor tract seeding. A study by Yamada *et al.* suggests that there is no correlation between number of biopsy

passes and tumor seeding.^[10] No studies have directly evaluated tumor seeding rates between biopsies with or without coaxial needles. Maturen *et al.* had zero cases of tumor seeding after 1012 liver lesions using a coaxial cutting needle technique.^[11] However, this study may not have been adequately powered due to the fact that only 128 of these lesions turned out to be malignant and the incidence of tumor seeding is so low.

Studies have demonstrated increased tumor seeding with increasing needle size.^[12] The use of a coaxial needle effectively increases the needle size and may have played a role in our patients' tumor seeding. These studies also suggest that tumor seeding would be more likely to occur with a biopsy gun compared to a smaller needle used for FNA.

To the best of our knowledge, this is the first case of a patient with squamous cell carcinoma developing tract seeding after biopsy of a metastatic adrenal lesion. Voravud *et al.* reported a similar case in 1990.^[13] However, their patient's primary malignancy was adenocarcinoma and was never pathologically proven.

Declaration of patient consent

The authors certify that they have obtained all appropriate patient consent.

Financial support and sponsorship

Nil.

Conflicts of interest

There are no conflicts of interest.

REFERENCES

1. Seyfer AE, Walsh DS, Graeber GM, Nuno IN, Eliasson AH. Chest wall implantation of lung cancer after thin-needle aspiration biopsy. *Ann Thorac Surg* 1989;48:284-6.
2. Kline TS, Neal HS. Needle aspiration biopsy: A critical appraisal. Eight years and 3,267 specimens later. *JAMA* 1978;239:36-9.
3. Cardella JF, Bakal CW, Bertino RE, Burke DR, Drooz A, Haskal Z, *et al.* Quality improvement guidelines for image-guided percutaneous biopsy in adults. *J Vasc Interv Radiol* 2003;14:S227-30.
4. Silva MA, Hegab B, Hyde C, Guo B, Buckels JA, Mirza DF, *et al.* Needle track seeding following biopsy of liver lesions in the diagnosis of hepatocellular cancer: A systematic review and meta-analysis. *Gut* 2008;57:1592-6.

5. Volanis D, Neal DE, Warren AY, Gnanapragasam VJ. Incidence of needle-tract seeding following prostate biopsy for suspected cancer: A review of the literature. *BJU Int* 2015;115:698-704.
6. Polyzos SA, Anastasilakis AD. A systematic review of cases reporting needle tract seeding following thyroid fine needle biopsy. *World J Surg* 2010;34:844-51.
7. Sinner WN, Zajicek J. Implantation metastasis after percutaneous transthoracic needle aspiration biopsy. *Acta Radiol Diagn (Stockh)* 1976;17:473-80.
8. Kim JH, Kim YT, Lim HK, Kim YH, Sung SW. Management for chest wall implantation of non-small cell lung cancer after fine-needle aspiration biopsy. *Eur J Cardiothorac Surg* 2003;23:828-32.
9. Mu F, Liu SP, Zhou XL, Chen JB, Li HB, Zuo JS, *et al.* Prevention of needle-tract seeding by two-step freezing after lung cancer biopsy. *Pathol Oncol Res* 2013;19:447-50.
10. Yamada N, Shinzawa H, Ukai K, Wakabayashi H, Togashi H, Takahashi T, *et al.* Subcutaneous seeding of small hepatocellular carcinoma after fine needle aspiration biopsy. *J Gastroenterol Hepatol* 1993;8:195-8.
11. Maturen KE, Nghiem HV, Marrero JA, Hussain HK, Higgins EG, Fox GA, *et al.* Lack of tumor seeding of hepatocellular carcinoma after percutaneous needle biopsy using coaxial cutting needle technique. *AJR Am J Roentgenol* 2006;187:1184-7.
12. Tung WC, Huang YJ, Leung SW, Kuo FY, Tung HD, Wang JH, *et al.* Incidence of needle tract seeding and responses of soft tissue metastasis by hepatocellular carcinoma postradiotherapy. *Liver Int* 2007;27:192-200.
13. Voravud N, Shin DM, Dekmezian RH, Dimery I, Lee JS, Hong WK, *et al.* Implantation metastasis of carcinoma after percutaneous fine-needle aspiration biopsy. *Chest* 1992;102:313-5.

How to cite this article: Leshen M, Cantos A. Squamous Cell Carcinoma Tumor Seeding after Percutaneous Biopsy: A Rare Complication. *Am J Interv Radiol* 2019;3(1) 1-4.

AJIR