

GI/GU/Thoracic/Non-Vascular Interventions Original Research

## Percutaneous transhepatic biliary stone removal: A single-center retrospective study

James Kiujing Fung<sup>1</sup>, Warren Kam Wing Leung<sup>1</sup>, Kendrick Yip Kan Tang<sup>1</sup>, Wai Kuen Kan<sup>1</sup>

<sup>1</sup>Department of Radiology, Pamela Youde Nethersole Eastern Hospital, Chai Wan, Hong Kong.



**\*Corresponding author:**

James Kiujing Fung,  
Department of Radiology,  
Pamela Youde Nethersole  
Eastern Hospital, Chai Wan,  
Hong Kong.

[jamesfung@gmail.com](mailto:jamesfung@gmail.com)

Received : 30 November 2022

Accepted : 24 December 2022

Published : 16 January 2023

**DOI**

10.25259/AJIR\_34\_2022

**Quick Response Code:**



### ABSTRACT

**Objectives:** To report, the authors' experience with percutaneous transhepatic biliary stone removal, focusing on the technical aspects and overall performance, as well as reviewing few challenging cases.

**Material and Methods:** All cases of percutaneous transhepatic biliary stone removal from 2015 to 2022 were retrieved, including intrahepatic locations. Cases with negative initial cholangiogram suggestive of stone passage were excluded from the study. The demographic data, procedural indications and details, stone characteristics, fluoroscopic images, success rate, and complications were retrospectively evaluated by two experienced observers.

**Results:** The final study included 67 patients (mean age = 76.8). Majority of indications were altered gastric anatomy and failed endoscopic retrograde cholangiopancreatography. The mean largest stone size was 9 mm and most cases had multiple stones. Balloon sphincteroplasty was performed in all cases and mechanical lithotripsy in 24%. Fourteen cases required repeated trials, and they were mostly staged, depending on technical factors and patient condition. Recurrent pyogenic cholangitis (RPC) usually required repeated trials, and two separate sites of catheterization were made in the same lobe for one challenging case. Complete stone retrieval was not achieved in 9% (six out of 67) of cases: failure of mechanical lithotripsy ( $n = 2$ ); failure of balloon occlusion technique ( $n = 1$ ); refluxed stone ( $n = 1$ ); and multiplicity of intrahepatic stones ( $n = 2$ ). Three minor complications were encountered, including sepsis and self-controlled hemobilia. No major complications.

**Conclusion:** Percutaneous extrahepatic biliary stone removal is a safe and technically feasible procedure after a failed endoscopic approach or altered biliary tract anatomy. Cases of RPC or previous Whipple's operation could be technically challenging. Careful pre-procedural planning and anatomical review are crucial.

**Keywords:** Catheter, Choledocholithiasis, Hepatolithiasis, Interventional radiology, Percutaneous biliary stone removal

### INTRODUCTION

Endoscopic retrograde cholangiopancreatography (ERCP) is the first-line treatment for symptomatic biliary stones, but its role remains limited by technical and disease factors such as altered biliary tract anatomy, large stone size, or difficult cannulation. Transhepatic biliary stone removal is a promising and safe non-surgical alternative for symptomatic biliary stones, including hepatolithiasis, which is more prevalent in the East Asian countries and usually imposes technical challenge due to associated strictures.<sup>[1-3]</sup>

In this study, we sought to evaluate the technical success rate in percutaneous transhepatic biliary stone removal in our institution over a 7-year span. The technical perspectives of challenging or failed cases were reviewed.

This is an open-access article distributed under the terms of the Creative Commons Attribution-Non Commercial-Share Alike 4.0 License, which allows others to remix, transform, and build upon the work non-commercially, as long as the author is credited and the new creations are licensed under the identical terms.

©2023 Published by Scientific Scholar on behalf of American Journal of Interventional Radiology

## MATERIAL AND METHODS

All cases of percutaneous transhepatic biliary stone removal from 2015 to 2022 in our institution were retrospectively retrieved and reviewed. Cases with negative initial cholangiogram suggestive of stone passage were excluded from the study.

The demographic data, procedural details, and stone characteristics were recorded by two observers. The outcome measurements included success rate, number of repeats, and short-term procedural-related complications. Procedural success was defined as fluoroscopic ductal clearance, while procedural-related complications were tracked up to 30 days following the latest procedure.

All computed tomography and fluoroscopic images were reviewed on the PACS system. All statistical analyses were performed using IBM SPSS Statistics 18.0. Categorical variables were presented as number and percentage. Continuous data were presented as mean  $\pm$  standard deviation.

A standard procedure includes insertion of a percutaneous transhepatic biliary drainage (PTBD) catheter 2 weeks before for tract maturation and decompression of the biliary ductal system. Initial cholangiography maps the anatomy, which confirms the location and number of stones, corresponding ductal diameter, and presence of any strictures, which guide subsequent choice of balloon catheter and lithotripsy device.

A flexible introducer sheath (8-Fr Super Arrow-Flex sheath, Teleflex Medical, Athlone, Ireland) was first introduced through a 0.035-inch guidewire (UltraStiff guidewire, Cook Medical, Bloomington [IN], US; Super Stiff guidewire, Boston Scientific, Natwick [MA], US). Balloon dilatation of the Sphincter of Oddi followed, with an angioplasty balloon sized from 8 to 12 mm (Mustang balloon dilatation catheter; Boston Scientific, Natwick [MA], US). The balloon size was kept below 12 mm to avoid bleeding or rupture of the sphincter. The balloon was positioned symmetrically across the ampulla, inflated with diluted contrast until the waist disappeared. A 6- to 7-Fr Fogarty balloon catheter (Edwards Lifesciences, Irvine [CA], US) was then introduced over the guidewire. The inflated Fogarty balloon was, then, advanced over the guidewire to expel the biliary stones into the duodenum.

For larger stone size, usually above 10 mm, or intrahepatic stones with anticipated difficulty, mechanical lithotripsy (LithoCrushV, Olympus Medical Systems, Tokyo, Japan) was employed. The main components of the mechanical lithotripter are a basket, a traction wire, and a metallic introducer sheath. The stone was first captured by the basket. Tension was applied through the traction wire, and the stone was crushed by mechanical shear force between the metal sheath and the basket. Strictures were addressed in a

similar manner as sphincteroplasty, with the aforementioned angioplasty balloon. This step could be repeated multiple times when necessary.

All procedures were performed by three interventional radiologists with at least 9 years of clinical experience. Prophylactic broad-spectrum antibiotics were prescribed. The biliary system was properly decompressed after the procedure to reduce incidence of biliary sepsis and acute pancreatitis.

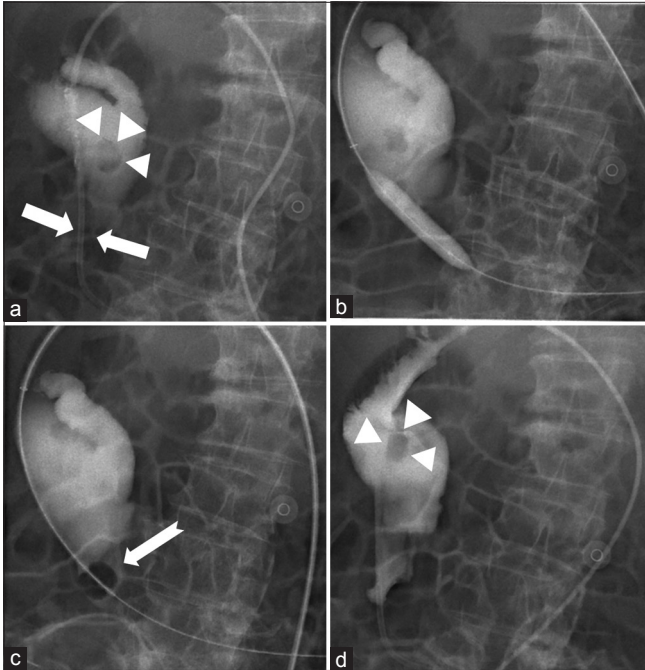
## RESULTS

The final study included 84 procedures in 67 consecutive patients, with a mean age of 76.8. Procedural indications and stone characteristics are summarized in [Table 1]. For the ten cases of intrahepatic stones, there were four cases of previous Whipple's operation and three known recurrent pyogenic cholangitis (RPC).

**Table 1:** Patient demographics, indications of procedure, stone characteristics, and outcome measurements summarized.

Characteristic(s)	Corresponding data
Total number of patients	67
Patient demographics	
Mean age	76.8 $\pm$ 10.1 (range 49–92)
Gender	
Male	44 cases (65.7%)
Female	23 cases (34.3%)
Indications	
Failure of ERCP cannulation	27 cases (40.2%)
Prior surgery	
Gastric	29 cases (43.3%)
Whipple's operation	5 cases (7.4%)
Others	1 case (1.5%)
Recurrent pyogenic cholangitis	5 cases (7.4%)
Stone characteristics	
Mean diameter of largest stone	9.2 $\pm$ 4.3 mm (range 3–25)
Multiple stones	39 cases (58.2%)
Intrahepatic stone location	10 cases (14.9%)
Complete stone removal	
Achieved	61 cases (91.0%)
One session	49 cases
Two sessions	10 cases
Three sessions	2 cases
Not achieved	6 cases (9.0%)
One session	4 cases
Two sessions	2 cases
Required mechanical lithotripsy	
Yes	16 cases (23.9%)
No	51 cases (76.1%)
Post-procedural complication	
Major	0 cases
Minor	3 cases (4.5%)

ERCP: Endoscopic retrograde cholangiopancreatography

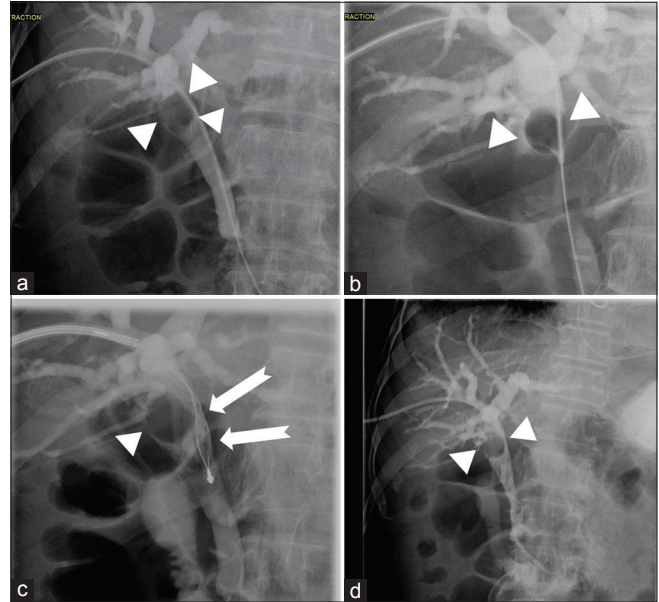


**Figure 1:** A 83-year-old male patient presented with deranged liver function. (a) Percutaneous transhepatic biliary drainage cholangiogram showed grossly dilated and angulated common bile duct with a small stone (arrowheads) and a stricture at the distal end (arrows). (b) Dilatation of the stricture with a 10 × 40 mm Mustang balloon. (c) 7Fr Fogarty balloon (notched arrow) failed to engage the stone in the capacious duct despite repeated attempts. (d) Post-procedural cholangiogram showed persistent common duct stone (arrowheads).

Complete stone removal was achieved in 91% (61 out of 67) of cases. Of the six failed cases, three were technically limiting and two were related to multiplicity of intrahepatic stones. One case had a refluxed intra-hepatic stone presumed to be caused by guidewire manipulation. These cases are, further, elaborated in the following discussion session.

The majority of cases required single procedure for ductal clearance. Twelve cases required an extra procedure; these cases usually contained multiple stones or associated stricture that required staged removal. Two cases required a further third attempt, including a case of hepaticojejunostomy with intrahepatic duct (IHD) strictures and a case of previous Whipple's operation with confluence stricture and intrahepatic stones requiring staged removal. Complete stone removal was eventually achieved in both cases.

Three cases of post-procedural complication were reported. Two cases developed fever and leukocytosis after the procedure which resolved shortly with intravenous broad-spectrum antibiotics. One case had self-limiting hemobilia coupled with hemoglobin drop. The patient remained clinically stable, while urgent CT angiogram study did not



**Figure 2:** A 90-year-old female with previous gastric surgery presented with deranged liver function. (a) Percutaneous transhepatic biliary drainage (PTBD) cholangiogram showed a 20 mm stone (arrowheads) at the ductal confluence. (b) Balloon occlusion technique displaced the stone (arrowheads) slightly inferiorly to the upper common duct. (c) LithoCrushV device (notched arrow) failed to capture the impacted stone (arrowheads). (d) Post-procedural cholangiogram showed residual stone (arrowhead) at the upper common duct. The patient was put on long-term PTBD in view of poor general condition and multiple comorbidities.

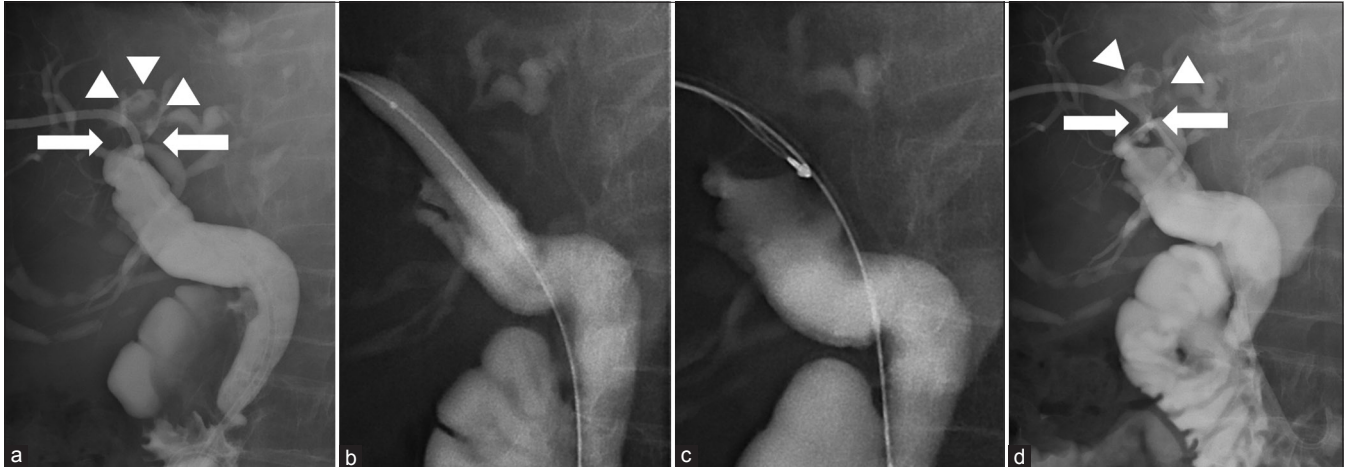
demonstrate evidence of active bleeding. Major complications were not encountered in all 84 procedures.

## DISCUSSION

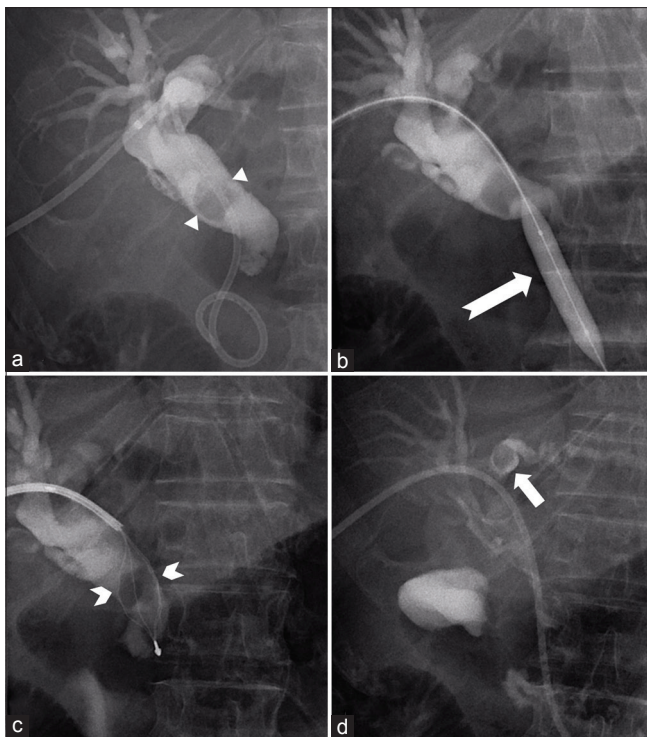
Percutaneous biliary stone removal has been an established second-line treatment following failed or contraindicated ERCP, since its first report in 1962 by Mondet *et al.*<sup>[4]</sup> The Dormia stone basket and occlusion balloon techniques are safe and effective maneuvers introduced by Burhenne and Gil *et al.*, respectively.<sup>[5,6]</sup> Sphincteroplasty is also widely practiced, which was shown to reduce residual ampulla stones and hence the number of procedures. Transcholecystic approach was also practiced.<sup>[7]</sup> There are a few technical advantages of percutaneous approach over ERCP. First, the stones are removed in an antigrade manner. Second, a shorter and more direct path can be obtained to avoid wire kinking and to better transmit the force for stone expulsion.

In this retrospective study, we reviewed the success rate and some challenging cases of percutaneous biliary stone removal in our institution over a 7-year span. An overall technical successful rate of 91% was achieved, in line with the 88% threshold suggested by the Society of Interventional





**Figure 3:** A 88-year-old female presented with biliary sepsis. Failed ERCP. (a) Preliminary percutaneous transhepatic biliary drainage cholangiogram demonstrated a stricture (white arrows) at the proximal right intrahepatic duct (IHD), and a 11 mm filling defect (arrowheads) distally. (b) Stricture dilated by 8 × 40 mm Mustang Balloon. Followed by repeated balloon occlusion manoeuvres which failed to expel stone into the common duct. (c) LithoCrushV deployed over 10Fr arrow sheath. Basket failed to expand properly due to small intrahepatic calibre. (d) Post-procedural cholangiogram showed persistent stricture (white arrows) and right IHD filling defect (arrowheads).



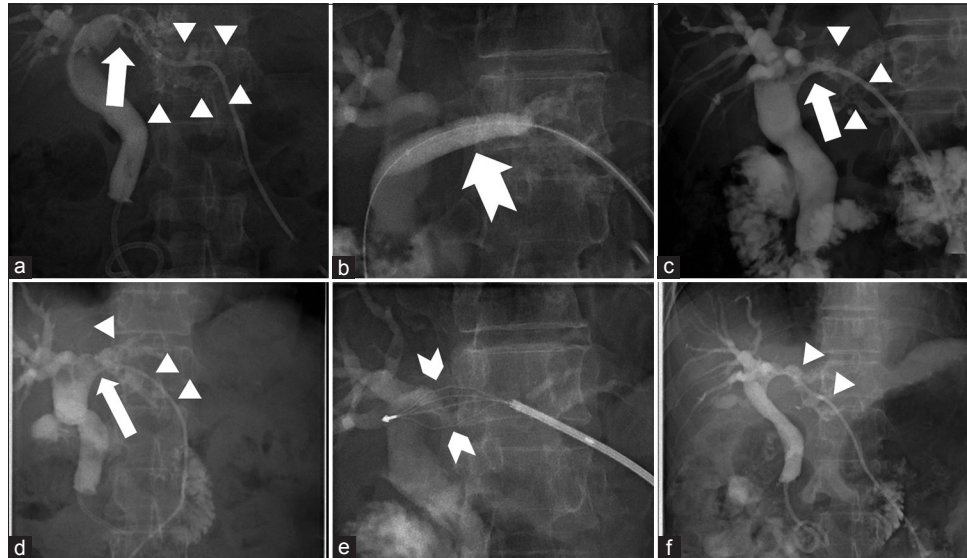
**Figure 4:** A 64-year-old male patient presented with jaundice. (a) Percutaneous transhepatic biliary drainage (PTBD) cholangiogram showed common ductal stones (arrowheads) up to 15 mm in size. (b) Sphincteroplasty with a 10 × 40 mm Mustang balloon (notched arrow). (c) LithoCrushV device (notched arrowheads) captured the largest stone. The stone fragments were subsequently expelled to the duodenum by Fogarty balloon (not shown). (d) Check angiogram showed a refluxed stone (small white arrow) in the left intrahepatic duct. The ductal stone was not seen in follow-up PTBD cholangiogram 1 month after (not shown).

Radiology, as well as the widely accepted 85–95% for endoscopic approach.<sup>[8]</sup>

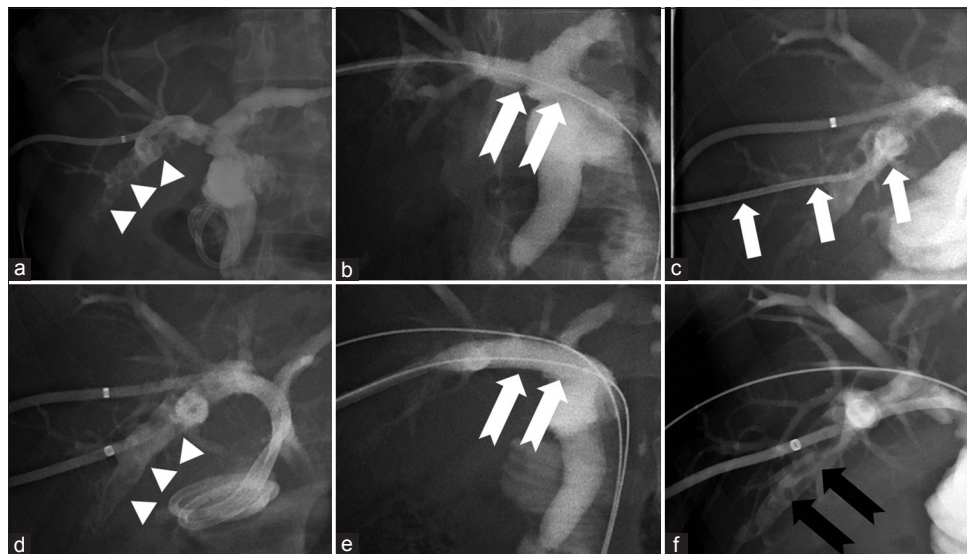
Complete stone removal was not achieved in six cases. One case had a grossly dilated common duct, where the Fogarty balloon failed to engage the stone [Figure 1]. Two cases were related to failure of basket lithotripsy; one with large stone size failed to be captured by the basket [Figure 2], and the other with a small intrahepatic ductal caliber, where the basket failed to expand properly [Figure 3]. Another case had a small common duct stone refluxed to the left main IHD presumably during guidewire manipulation [Figure 4]. The ductal stone was not seen in follow-up PTBD cholangiogram 1 month after. The remaining two cases were related to multiplicity of intrahepatic stones in a case of RPC [Figure 5] and prior hepaticojejunostomy [Figure 6].

For hepatolithiasis, a wide range of technical success rates (61.5–94%) were reported in retrospective studies and were considered lower compared with choledocholithiasis.<sup>[2,9]</sup> For the ten cases of hepatolithiasis in our study, two failed to achieve complete stone removal, giving a comparable individual success rate of 80%.

Our study included five cases of RPC. This condition is more prevalent in the East Asian population and usually poses more technical challenges due to multifocal stone locations and associated strictures.<sup>[10]</sup> Recurrence in hepatolithiasis is shown to be related to strictures and presence of stones in both lobes.<sup>[11]</sup> Percutaneous methods, most commonly percutaneous transhepatic cholangioscopic lithotomy, show inferiority in recurrence rates compared with definitive surgeries, but still play a major role in treating obstructions and alleviating cholangitis.<sup>[9]</sup> In addition, surgery is usually



**Figure 5:** A 50-year-old female with known RPC presented with fever. Fluoroscopic images from the first (a-c) and staged second trials (d-f). (a) Percutaneous transhepatic biliary drainage (PTBD) cholangiogram showed a left intrahepatic duct (IHD) stricture (arrow) and innumerable small ductal stones (arrowheads). (b) Application of 10 × 40 mm Mustang balloon (notched arrow) to the left IHD stricture, followed by repeated balloon occlusion technique to expel stones into the duodenum (not shown). (c) Check angiogram showed improvement of the stricture (arrow) and less residual ductal stones (arrowheads). (d) PTBD cholangiogram showed persistent left IHD stricture (arrow) and multiple small ductal stones (arrowheads). (e) LithoCrushV device (notched arrowheads) captured and crushed the ductal stones. (f) Check cholangiogram showed less residual ductal stones (arrowheads). No filling defects in the common duct.



**Figure 6:** A 71-year-old man with the previous hepaticojejunostomy presented with deranged liver function and sepsis. Fluoroscopic images obtained in first (a-d) and second (e-f) trials. (a) PTBD cholangiogram showing multiple stones (arrowheads) in few right posterior sectoral ducts. (b) Dilatation of the proximal intrahepatic duct (IHD) by a 6 × 40 mm Mustang balloon (notched arrows), followed by standard balloon occlusion technique. (c) Another PTBD catheter (arrows) inserted in an adjacent stone-filled duct. (d) Check cholangiogram by the end of the first trial showed persistent right posterior sectoral ductal stones (arrowheads). (e) Repeated dilatation of proximal IHD by 7 × 40 mm Mustang balloon (notched arrows). (f) Check cholangiogram by the end of the second trial confirmed interval reduction of ductal stones (black notched arrows).

implicated for single-segment involvement and is considered high risk for chronic cases who developed biliary cirrhosis. Despite the technical demands, the limited cases in our study showed satisfactory stone clearance rate (four out of five cases, 80%) and absence of complications.

In our series, 16 cases had large stone size of 10 mm or above. All received mechanical lithotripsy with the basket snare technique, and it was unsuccessful in two cases due to failure of stone capture and basket expansion as described and annotated previously. The individual success rate of 87.5% from our study was considered satisfactory. Various lithotripsy methods, including intracorporeal electrohydraulic lithotripsy, laser lithotripsy, and electromagnetic lithotripsy, are available and demonstrate promising results, but are commonly expensive and require expertise.

There were limitations to our study. First, difference in referral criterion and threshold between clinical teams and the single institution design could introduce selection bias to the study population, limiting generalizability of the result. Second, it was not our routine practice to tackle gallbladder stones. This is quite commonly practiced in the Western countries, where dropped stones account for majority of the ductal stones.

## CONCLUSION

Percutaneous biliary stone removal with Fogarty technique and basket lithotripsy is safe and technically feasible. Large stone size, previous RPC, or Whipple's operation with hepatolithiasis, could be technically challenging. Satisfactory technical success rate can be achieved in these cases with careful pre-procedural planning and proper use of equipment. Future generalizable studies can be targeted at percutaneous treatments for hepatolithiasis.

## Acknowledgment

This study was approved by the Hong Kong East Cluster Research Ethics Committee (reference number: HKECREC-2022-060).

## Authors contributions

All authors are involved in the concepts, design, and literature of the study. JKF performed data acquisition and statistical analysis. JKF, WKWL, and KYKT prepared and reviewed the manuscript.

## Declaration of patient consent

Patient's consent not required as patients identity is not disclosed or compromised.

## Financial support and sponsorship

Nil.

## Conflicts of interest

There are no conflicts of interest.

## REFERENCES

- Seon HG, Kwon CI, Yoon SP, Yoo KH, Ok CS, Kim WH, *et al.* PTPBD for managing extrahepatic bile duct stones in patients with failed or contraindicated ERCP. *Korean J Med* 2012;83:65-74.
- Ozcan N, Kahriman G, Mavili E. Percutaneous transhepatic removal of bile duct stones: Results of 261 patients. *Cardiovasc Intervent Radiol* 2012;35:621-7.
- Tazuma S. Gallstone disease: Epidemiology, pathogenesis, and classification of biliary stones (common bile duct and intrahepatic). *Best Pract Res Clin Gastroenterol* 2006;20:1075-83.
- Mondet AF. Technic of blood extraction of calculi in residual lithiasis of the choledochus. *Bol Trab Soc Cir B Aires* 1962;46:278-90.
- Burhenne HJ. Garland lecture. Percutaneous extraction of retained biliary tract stones: 661 patients. *AJR Am J Roentgenol* 1980;134:889-98.
- Gil S, de la Iglesia P, Verdú JF, de España F, Arenas J, Irurzun J. Effectiveness and safety of balloon dilation of the papilla and the use of an occlusion balloon for clearance of bile duct calculi. *AJR Am J Roentgenol* 2000;174:1455-60.
- Jung GS, Kim YJ, Yun JH, Park JG, Yun BC, Han BH, *et al.* Percutaneous transcholecystic removal of common bile duct stones: Case series in 114 patients. *Radiology* 2019;290:238-43.
- Devane AM, Annam A, Brody L, Gunn AJ, Himes EA, Patel S, *et al.* Society of Interventional radiology quality improvement standards for percutaneous cholecystostomy and percutaneous transhepatic biliary interventions. *J Vasc Interv Radiol* 2020;31:1849-56.
- Cheon YK, Cho YD, Moon JH, Lee JS, Shim CS. Evaluation of long-term results and recurrent factors after operative and non-operative treatment of hepatolithiasis. *Surgery* 2009;146:843-53.
- Tsui WM, Lam PW, Lee WK, Chan YK. Primary hepatolithiasis, recurrent pyogenic cholangitis, and oriental cholangiohepatitis: A tale of 3 countries. *Adv Anat Pathol* 2011;18:318-28.
- Cheung MT, Wai SH, Kwok PC. Percutaneous transhepatic choledochoscopic removal of intrahepatic stones. *Br J Surg* 2003;90:1409-15.

**How to cite this article:** Fung JK, Leung WK, Tang KY, Kan WK. Percutaneous transhepatic biliary stone removal: A single-center retrospective study. *Am J Interv Radiol* 2023;7:2.