

## Interventional Oncology Case Report

# Treatment of hepatocellular carcinoma with arterioportal shunting using balloon-assisted transarterial yttrium-90 radiation segmentectomy: A case report

Peter Kolyvas<sup>1</sup>, Moutasem Aljundi<sup>2</sup>, Gajan Sivananthan<sup>2</sup>

<sup>1</sup>Department of Interventional Radiology, Georgetown School of Medicine, Washington, United States, <sup>2</sup>Department of Interventional Radiology, MedStar Washington Hospital Center, Washington, United States.



### \*Corresponding author:

Gajan Sivananthan,  
Department of Interventional  
Radiology, MedStar  
Washington Hospital Center,  
Washington, United States.

[gajan.sivananthan@medstar.net](mailto:gajan.sivananthan@medstar.net)

Received : 13 March 2023

Accepted : 11 April 2023

Published : 06 May 2023

### DOI

10.25259/AJIR\_17\_2023

### Quick Response Code:



## ABSTRACT

Portal vein tumor thrombus (PVTT) is a common finding associated with hepatocellular carcinoma (HCC) often further complicated by arterioportal shunting. While radioembolization with Yttrium-90 (Y-90) is the preferred treatment for HCC with PVTT, shunting can complicate particle delivery. Here, we describe a case of a 65-year-old man with HCC and significant shunting from the segment IV hepatic artery into the left and right portal veins due to a PVTT. We performed a balloon-assisted radiation segmentectomy by occluding the hepatic artery supplying the PVTT to minimize arterioportal shunting and promote redistribution of particles into the tumor bed. Post Y-90 bremsstrahlung scan correlated with appropriate uptake. One-month follow-up magnetic resonance imaging demonstrated response to treatment with decreased tumor thrombus in the left portal vein. Here, we demonstrate that balloon-occlusion-assisted transarterial radiation segmentectomy could be a beneficial approach for improving tumor response and reducing complications in individuals with HCC and arterioportal shunting.

**Keywords:** Balloon-occlusion microcatheter, Case report, Hepatocellular carcinoma, Portal vein tumor thrombus, Y-90 radioembolization

## INTRODUCTION

Radioembolization with Yttrium-90 (Y-90) is the locoregional treatment of choice in patients with hepatocellular carcinoma (HCC) and portal vein tumor thrombus (PVTT). Radiation segmentectomy, defined as radioembolization of two or fewer segments of the liver, has been shown to improve outcomes in patients with PVTT when doses >205 Gy are utilized compared with those patients who receive lower doses.<sup>[1,2]</sup> Unfortunately, arterioportal venous shunts (APS), often seen concurrently with HCC PVTT, have been hypothesized to decrease the response to treatment and increase adverse events. This is thought to be a result of poor implantation of microparticles in the tumor as the particles exit through the capillary bed without stasis, reducing the therapeutic dose, and increasing the rate of adverse events by redistributing particles to non-target liver segments.<sup>[3]</sup> This shunting is often minor and limited to the tumor-involved segment or lobe. Rarely, a major shunt can result in shunting to both the involved and uninvolved lobes as well as the extrahepatic portal system. In these patients with major shunts, segmentectomy dosing cannot be delivered as the dose would be redistributed to the entire liver.<sup>[4]</sup> We describe

This is an open-access article distributed under the terms of the Creative Commons Attribution-Non Commercial-Share Alike 4.0 License, which allows others to remix, transform, and build upon the work non-commercially, as long as the author is credited and the new creations are licensed under the identical terms.

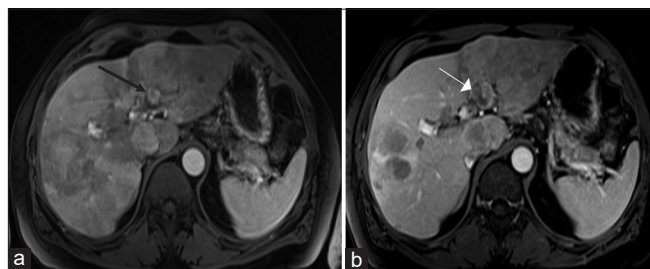
©2023 Published by Scientific Scholar on behalf of American Journal of Interventional Radiology

a case where we used a balloon-occlusion microcatheter in the hepatic artery supplying PVTT to minimize arteriportal shunting and promote redistribution of particles into the tumor bed, specifically the PVTT component, during Y-90 glass microspheres radiation segmentectomy in a patient with HCC and APS. The Institutional Review Board approval was not required for this report.

## CASE REPORT

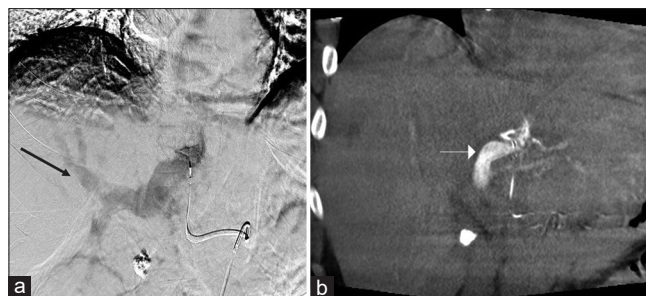
A 65-year-old male with hepatitis C cirrhosis, chronic kidney disease, and recently diagnosed HCC presented with abdominal pain, decreased appetite, and weight loss. He was risk stratified as Child-Pugh 5A, albumin-bilirubin grade 1, and eastern cooperative oncology group grade 1 and referred for Y-90 treatment. Magnetic resonance imaging (MRI) demonstrated extensive bilobar HCC with enhancing tumor thrombus in the left portal vein as well as porta hepatis nodal metastasis [Figure 1]. At presentation, vital signs were within normal limits, total bilirubin level was 0.2 mg/dL, and alpha-fetoprotein was 9.6 ng/mL (normal range, <10 ng/mL). Given the extensive liver-centered malignancy burden with vascular invasion in the setting of preserved liver function and functional status, the decision was made to proceed with radioembolization with planned segmentectomy dose to the PVTT and lobar treatment to the left lobe.

Digital subtraction angiogram (DSA) performed through a conventional microcatheter in the left hepatic artery demonstrated rapid shunting into the left and right portal veins. Similarly, a DSA with the sniper microcatheter (Embolix, Los Altos, California) with the balloon deflated and positioned in the segment IV branch of the left hepatic artery demonstrated subtle tumor blush in the left lobe with quick opacification of the right and left portal veins [Figure 2a]. Cone-beam computed tomography (CBCT) was performed with a rate of 1 mL/s for a total volume of 10 mL and demonstrated

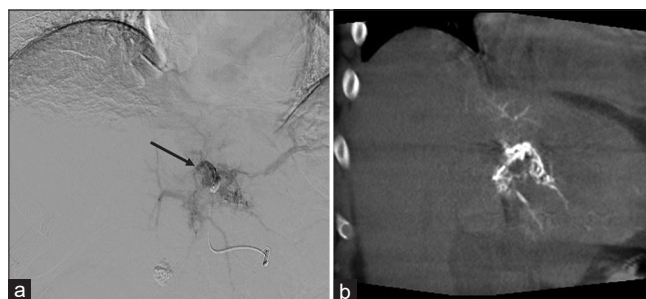

**Figure 1:** A 65-year-old male with bilobar hepatocellular carcinoma and enhancing tumor thrombus in the left portal vein who presented with abdominal pain, decreased appetite, and weight loss. (a) Axial T1-weighted magnetic resonance imaging post contrast images in arterial phase showing multiple enhancing masses throughout the liver with arterially enhancing tumor thrombus in the left portal vein (black arrow) and (b) delayed phase with delayed washout (white arrow).

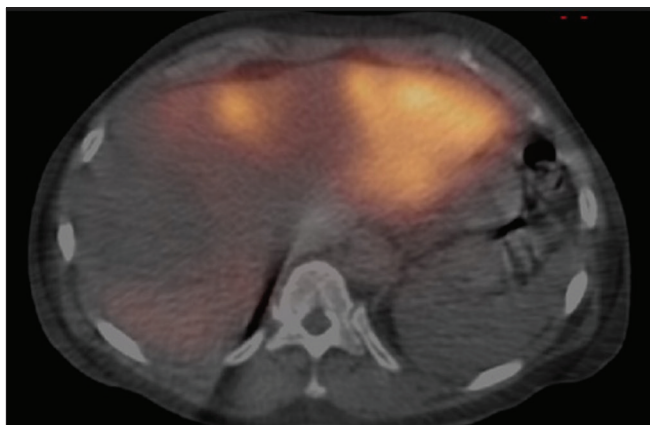
enhancement of the right and left hepatic lobe parenchyma [Figure 2b]. Repeat DSA and CBCT with balloon occlusion of the segment IV branch demonstrated improved tumor enhancement without arteriportal shunting into the right lobe [Figure 3a and b]. Tc-99 m macroaggregated albumin (MAA) was administered into segment IV during balloon occlusion and single-photon emission computed tomography-computed tomography demonstrated high activity in the left lobe tumor as well as the left portal vein thrombus with minimal uptake in the right hepatic lobe [Figure 4]. Pre-treatment Tc-99m MAA scintigram demonstrated a lung shunt of 10% and perfused volume of 790 mL. The left lobe of the liver, including the left PVTT, was treated with Y-90 glass microspheres (BTG International, Ottawa, Canada) utilizing balloon occlusion in the same fashion. The total activity delivered was 4.878 GBq, with a 286 Gy dose delivered to the perfused liver volume



**Figure 2:** 65-year-old male with bilobar hepatocellular carcinoma and enhancing tumor thrombus in the left portal vein who presented with abdominal pain, decreased appetite, and weight loss. (a) Digital subtraction angiography without balloon occlusion demonstrates minimal tumor blush and quick opacification of both left and right portal veins (black arrow). (b) Coronal contrast-enhanced cone beam computed tomography demonstrates opacification of the portal vein on arterial phase (white arrow) consistent with arteriportal shunting.



**Figure 3:** A 65-year-old male with bilobar hepatocellular carcinoma and enhancing tumor thrombus in the left portal vein who presented with abdominal pain, decreased appetite, and weight loss. (a) Digital subtraction angiography through the Sniper balloon microcatheter with balloon occlusion showing improved tumor enhancement in segment IV, including tumor thrombus in the left portal vein (black arrow). (b) Coronal contrast-enhanced cone beam computed tomography showing parenchymal enhancement in segment IV with much decreased arteriportal shunting.




**Figure 4:** A 65-year-old male with bilobar hepatocellular carcinoma and enhancing tumor thrombus in the left portal vein who presented with abdominal pain, decreased appetite, and weight loss. Axial single-photon emission computed tomography-computed tomography image after 99m TC macroaggregated albumin (MAA) administration into segment IV artery demonstrating high activity within the targeted tumor in segment IV and left hepatic lobe with minimal accumulation of MAA in the right hepatic lobe.

of 790 mL and a dose delivered to the lung of 24.39 Gy. Post Y-90 bremsstrahlung scan correlated with the mapping study [Figure 5]. There were no intraprocedural complications and 1-month follow-up MRI demonstrated response to treatment with decreased tumor thrombus in the left portal vein [Figure 6].

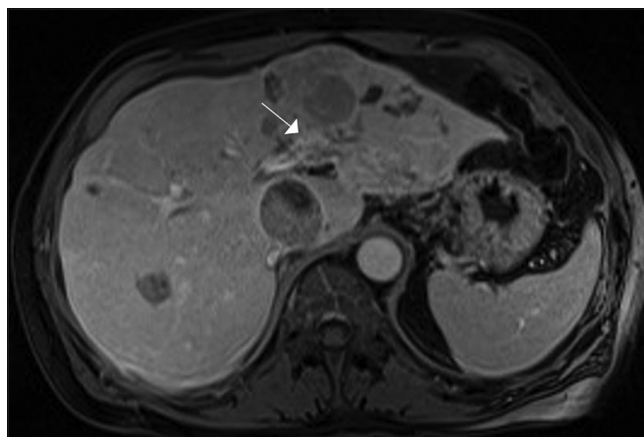
## DISCUSSION

The presence of arteriportal shunts in HCC impacts the efficacy and safety of radioembolization due to particles siphoning off through the shunt, potentially leading to underdosing of the target lesion and increased deposition of radiation in normal liver tissue leading to further liver damage. The risk of adverse events after radioembolization is highest with non-segmental and large shunts.<sup>[3]</sup> Permanent occlusion of some shunts is possible with various embolic agents including polyvinyl alcohol, lipiodol gelatin, sponge granules, cyanoacrylate, and coils and could potentially be followed by typical radioembolization.<sup>[5,6]</sup> However, these strategies carry additional risks including non-target embolization, portal vein occlusion, or proximal embolization thus preventing access to the tumor for future treatment.<sup>[7]</sup> To date, there are no clear guidelines in management of large APS due to PVTT.

This case demonstrates a technique that allows delivery of Y-90 beads to the target tumoral tissue in the setting of significant portal vein shunting that would otherwise redistribute the particles throughout the liver, resulting in insufficient dose to the tumor and high doses to non-target liver parenchyma. The occlusion balloon in the arterial side of the portal vein shunt decreases the pressure in the arterial



**Figure 5:** A 65-year-old male with bilobar hepatocellular carcinoma and enhancing tumor thrombus in the left portal vein who presented with abdominal pain, decreased appetite, and weight loss. Bremsstrahlung scan obtained post Y-90 glass microsphere treatment using balloon occlusion technique showing maximum activity in segment IV and the left hepatic lobe (white arrow) with minimal uptake in the right hepatic lobe.



**Figure 6:** A 65-year-old male with bilobar hepatocellular carcinoma and enhancing tumor thrombus in the left portal vein who presented with abdominal pain, decreased appetite, and weight loss. Post-treatment axial T1-weighted magnetic resonance imaging post-contrast image demonstrating improved tumor thrombus in the left portal vein (white arrow).

system compared to the portal vein, thereby reversing flow away from the shunt. The degree to which this happens is dependent on the intrahepatic collaterals that perfuse the target artery distal to the balloon.

## CONCLUSION

Balloon-occlusion-assisted transarterial radiation segmentectomy may be an effective method to increase tumor response and

decrease the rate of complications in patients with HCC and arterioportal shunting undergoing radiation segmentectomy. Future prospective studies may be warranted to determine the feasibility and safety of adding balloon-occlusion transarterial radioembolization segmentectomy to standardized treatment algorithms.

### Acknowledgments

This case was accepted as a poster at global embolization symposium technologies (GEST) 2023.

### Declaration of patient consent

Patient's consent not required as patient's identity is not disclosed or compromised.

### Financial support and sponsorship

We plan to apply for support from embolix to pay any publication/processing fee.

### Conflicts of interest

Dr. Sivananthan is a consultant for Boston Scientific and on the medical advisory board for Embolix inc.

### REFERENCES

1. Garin E, Lenoir L, Rolland Y, Edeline J, Mesbah H, Laffont S, *et al.* Dosimetry based on <sup>99m</sup>Tc-macroaggregated albumin

SPECT/CT accurately predicts tumor response and survival in hepatocellular carcinoma patients treated with <sup>90</sup>Y-loaded glass microspheres: Preliminary results. *J Nucl Med* 2012;53:255-63.

2. Riaz A, Gates VL, Atassi B, Lewandowski RJ, Mulcahy MF, Ryu RK, *et al.* Radiation segmentectomy: A novel approach to increase safety and efficacy of radioembolization. *Int J Radiat Oncol Biol Phys* 2011;79:163-71.
3. Thornton LM, Geller BS, Pepin EW, Shah JL, Kapp M, Toskich BB. Safety of radioembolization in the setting of angiographically apparent arterioportal shunting. *J Vasc Interv Radiol* 2018;29:1511-8.
4. Tan AE, Kao YH, Xie W. Excessive hepatic arterial-portal venous shunting may predict failure of microparticle localization in hepatocellular carcinomas. *World J Nucl Med* 2013;12:48-50.
5. Cao B, Tian K, Zhou H, Li C, Liu D, Tan Y. Hepatic arterioportal fistulas: A retrospective analysis of 97 cases. *J Clin Transl Hepatol* 2022;10:620-6.
6. Shi HB, Yang ZQ, Liu S, Zhou WZ, Zhou CG, Zhao LB, *et al.* Transarterial embolization with cyanoacrylate for severe arterioportal shunt complicated by hepatocellular carcinoma. *Cardiovasc Intervent Radiol* 2013;36:412-21.
7. Sheth RA, Sabir S, Krishnamurthy S, Avery RK, Zhang YS, Khademhosseini A, *et al.* Endovascular embolization by transcatheter delivery of particles: Past, present, and future. *J Funct Biomater* 2017;8:12.

**How to cite this article:** Kolyvas P, Aljundi M, Sivananthan G. Treatment of hepatocellular carcinoma with arterioportal shunting using balloon-assisted transarterial yttrium-90 radiation segmentectomy: A case report. *Am J Interv Radiol* 2023;7:12.