

## GI/GU/Thoracic/Non-Vascular Interventions Case Report

# Percutaneous CT-guided retrieval of a retained gallstone to treat a cutaneous fistula following cholecystectomy

Simon Peter Chivi<sup>1</sup>, Gregory Carbonella<sup>1</sup>

<sup>1</sup>Department of Radiology, Maimonides Health, Brooklyn, New York.



### \*Corresponding author:

Dr. Simon Peter Chivi,  
Department of Radiology,  
Maimonides Health, Brooklyn,  
New York.

simonchivi@gmail.com

Received : 07 May 2022

Accepted : 14 July 2022

Published : 01 August 2022

### DOI

10.25259/AJIR\_10\_2022

### Quick Response Code:



## ABSTRACT

This case report describes a technique for the removal of a subcutaneously retained gallstone in a patient who had previously undergone laparoscopic cholecystectomy. The patient's laparoscopic cholecystectomy was complicated by a perihepatic abscess which was drained percutaneously. The percutaneous abscess drainage was complicated by persistent drainage of tiny stones through the drain tract after the drainage catheter was removed. His computed tomography (CT) revealed a cutaneous fistula between the gallbladder fossa and the right flank with retained gallstones. Despite multiple outpatient general surgery visits, the patient's wound would not heal, and interventional radiology was consulted for management. Using CT guidance, a retained stone in the right flank was targeted, and a percutaneous approach involving serial dilation and retrieval with a 2.4F × 120 cm Boston Scientific Segura Hemisphere Stone Retrieval Basket (Boston Scientific, Marlborough, MA) through an 18F × 40 cm Cook Check-Flo Performer introducer sheath (Cook, Bloomington, IN) was performed. Similar techniques are used in retrieval of intraluminal objects; however, this is a case in which an object lodged within the soft tissues was retrieved using Seldinger technique.

**Keywords:** Computed tomography guided, Interventional radiology, Percutaneous, Retained gallstone retrieval

## INTRODUCTION

This case report describes a minimally invasive technique for retrieval of a retained gallstone that was embedded in subcutaneous tissues resulting in a cutaneous fistula. Image-guided foreign body removal often involves blunt dissection and surgical clamps to retrieve subcutaneous objects identified using fluoroscopy and computed tomography (CT).<sup>[1]</sup> Prior literature describes complications of spilled gallstones and recommends immediate retrieval of lost/spilled gallstones intraoperatively and surgical/percutaneous drainage of resultant abscesses. Invasive techniques are sometimes required to retrieve spilled stones, including open laparotomy.<sup>[2,3]</sup> A case report from 1993 describes a similar technique employed for the removal of stones from a patient with retained gallstones, but the technique is likely underutilized.<sup>[4]</sup> This case describes a minimally invasive option that may obviate the need for blunt dissection, laparoscopy, or even laparotomy. This case also demonstrates rapid resolution of a cutaneous fistula following successful removal of the offending stone.

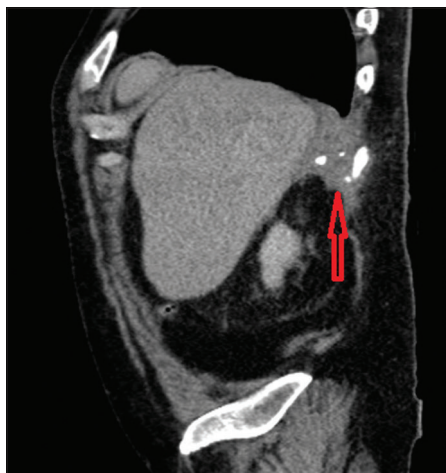## CASE REPORT

Our patient was a 64-year-old male with a medical history of hypertension, hyperlipidemia, and chronic obstructive pulmonary disease (COPD) in the setting of ½ pack per day

This is an open-access article distributed under the terms of the Creative Commons Attribution-Non Commercial-Share Alike 4.0 License, which allows others to remix, transform, and build upon the work non-commercially, as long as the author is credited and the new creations are licensed under the identical terms.

©2022 Published by Scientific Scholar on behalf of American Journal of Interventional Radiology

cigarette use who initially presented to the hospital with choledocholithiasis and cholangitis complicated by a COPD exacerbation secondary to respiratory syncytial virus. He endorsed vague postprandial abdominal pain for months before this visit, but he never followed up with a surgeon. He was found to have hyperbilirubinemia, elevated aminotransferases, and elevated alkaline phosphatase with CT of the abdomen and pelvis revealing choledocholithiasis. MRCP confirmed choledocholithiasis and cholecystitis. He initially underwent endoscopic retrograde cholangiopancreatography with stent placement and sphincterotomy, which was repeated post-discharge with stent retrieval and stone removal, ultimately followed by laparoscopic cholecystectomy. At his 2-week follow-up, his port sites were healing; however, he then presented to a nearby emergency department and was found to have a perihepatic abscess which was drained percutaneously. After his drain was removed, he noted passage of tiny stones through the drain tract. Follow-up CT revealed a right upper quadrant sinus tract with multiple stones in the right flank [Figure 1]. At his next outpatient follow-up visit with general surgery, he continued to endorse passage of tiny stones from his drainage site, and physical examination revealed a 4 mm persistent wound in the right flank. Tract flushing and silver nitrate cautery were attempted without success. Then, interventional radiology was consulted for retrieval of retained gallstone(s) refractory to conservative management. Using Seldinger technique, a needle, Cook Medical Percutaneous Entry Thinwall Needle 19G × 7 cm (Cook, Bloomington, IN), was advanced toward the stone [Figure 2a], through which a wire, Cook Medical Amplatz

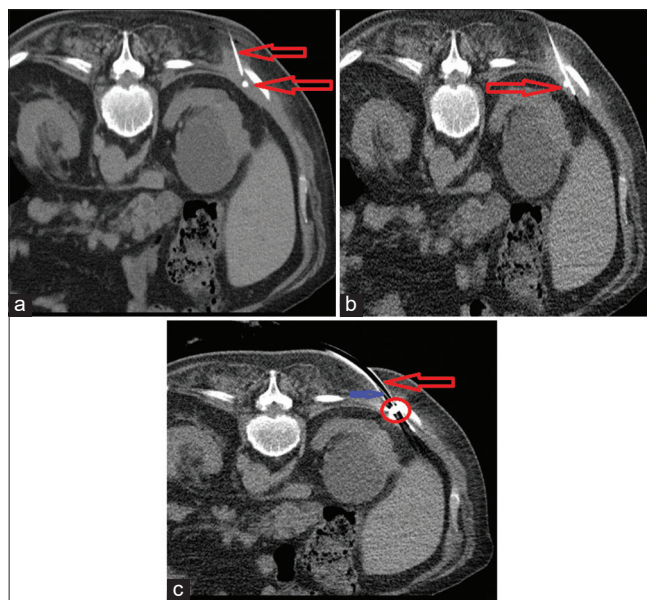


**Figure 1:** A 64-year-old male with surgical history of cholecystectomy found to have a post-operative abscess and a sinus tract with multiple calcified gallstones in the right flank. Contrast-enhanced computed tomography of the abdomen and pelvis, sagittal view reveals a post-operative abscess and multiple calcified stones in the posterior right upper quadrant (arrow).

Ultra Stiff Wire Guide 0.035" × 80 cm (Cook, Bloomington, IN), was advanced beyond the stone so the stiff body of the wire could support the sheath [Figure 2b]. The needle was removed, serial tract dilation was performed over the wire, and a sheath, 18F × 40 cm Cook Check-Flo Performer introducer sheath (Cook, Bloomington, IN), was advanced to the stone. An endoscopy basket, 2.4F × 120 cm Boston Scientific Segura Hemisphere Stone Retrieval Basket (Boston Scientific, Marlborough, MA), was advanced through the sheath and was successfully deployed to grasp the stone [Figure 2c]. The sheath was removed and the stone was sent to pathology, confirming a simple bile stone. At 3-week follow-up, the wound was completely healed and the patient's symptoms had resolved. No repeat imaging was performed (See supplemental data: Timeline of events).

## DISCUSSION

Laparoscopic cholecystectomy is the most performed elective abdominal surgery performed in the United States. Before the widespread adoption of laparoscopic cholecystectomy,



**Figure 2:** A 64-year-old male with cholecystectomy, post-operative abscess, retained gallstones, and cutaneous fistula. (a) Intraprocedural non-contrast computed tomography (CT) of the abdomen with the patient in the prone position demonstrates needle advancement to the subcutaneous stone (arrows). A 64-year-old male with cholecystectomy, post-operative abscess, retained gallstones, and cutaneous fistula. (b) Intraprocedural non-contrast CT of the abdomen with the patient in the prone position demonstrating wire advancement just beyond the stone (arrow). A 64-year-old male with cholecystectomy, post-operative abscess, retained gallstones, and cutaneous fistula. (c) Intraprocedural non-contrast CT of the abdomen with the patient in the prone position demonstrating endoscopy basket (blue arrow) within sheath (red arrow) grasping stone (red circle) and pulling it into the sheath.

spillage of gallstones was an infrequent complication of conventional open cholecystectomy. Spillage of gallstones into the peritoneum is recognized in 4% of laparoscopic cholecystectomies according to a 2018 systematic review.<sup>[3]</sup> The natural history of intraperitoneal stones was believed to be innocuous based on early animal models; however, later animal models dispelled this notion. Implantation of human gallstones into the peritoneal cavity of rats revealed that cholesterol stones led to abscess formation in association with Gram-negative bowel germs, sterile pigment stones led to granuloma formation, and contaminated pigment stones resulted in extensive abscess formation.<sup>[5,6]</sup> The most common complication in humans is abscess formation in either the abdominal wall, often within the trocar tract, or the peritoneum. Additional complications include cutaneous fistulas, colovesical fistulas, and incarcerated hernias; empyemas have also been reported.<sup>[7]</sup> Spilled gallstones may even mimic peritoneal carcinomatosis if not recognized early.<sup>[2,8]</sup>

Retained stones within the biliary system are often managed with common bile duct exploration or on-table cholangiography if they are noticed intraoperatively. If cholangiography is positive for stones, a post-operative ERCP is both diagnostic and therapeutic. Stones which spill into the peritoneum are associated with multiple complications. Unfortunately, diagnosis of dropped gallstones can be difficult given the limited view provided by laparoscopy, and the timeline for complications is broad, possibly occurring months to years after the operation. If spilled stones are noted intraoperatively, irrigation/dilution of bile with saline and basket or large forceps stone retrieval should be attempted. Conversion to open laparoscopy is generally reserved for more severe complications. The post-operative treatment is more complicated. Post-operative abdominal pain generally warrants imaging evaluation primarily looking for biliary injury, retained cystic duct, or common bile duct stones in the early phase and strictures, stenoses, stones, and dyskinesia in the late post-operative period. In cases of spilled stones, ultrasound may reveal small hyperechoic lesions usually in subdiaphragmatic or subhepatic spaces. Calcified stones may be visible as hyperdense lesions on CT or signal void on T1- or highly T2-weighted magnetic resonance imaging.<sup>[8,9]</sup>

While complications from laparoscopic cholecystectomy are less common than when it was first introduced, post-cholecystectomy syndrome remains an ongoing issue. A more recent 2015 study from the UK revealed complete resolution of abdominal pain after laparoscopic cholecystectomy only 60.5% of patients.<sup>[10]</sup> Persistently, symptomatic patients often have psychosomatic and non-biliary causes for their pain; however, spilled gallstones should be ruled out and addressed before assuming an unrelated etiology.<sup>[11]</sup>

## CONCLUSION

This report describes a case of laparoscopic cholecystectomy for calculous cholecystitis complicated by spillage of gallstones with perihepatic abscess and fistula formation treated using a minimally invasive technique involving a percutaneous approach for retrieving gallstones embedded within the abdominal wall. It also illustrates the insidious nature of spilled stones by describing the timeline from surgery to resolution of symptoms for our patient. The technique described may be considered in lieu of repeat laparoscopy or laparotomy and likely provides improved cosmesis and less soft-tissue injury when compared to blunt dissection and exploration. This technique is well described for retrieval of intraluminal objects. We demonstrate that Seldinger technique can also be utilized for objects lodged within the soft tissues obviating the need to return to the operating room and/or additional incision(s) possibly requiring anesthesia. The skills required are part and parcel of the experienced interventional radiologist's armamentarium, and even those without experience with this specific procedure could likely apply its principles in their own practice without additional training. Limitations of this technique include large stones which do not fit within the sheath, which may require more advanced techniques including lithotripsy before removal. This case also demonstrates that removing the nidus of inflammation leads to rapid healing of cutaneous fistulas.

## Declaration of patient consent

The authors certify that they have obtained all appropriate patient consent.

## Financial support and sponsorship

Nil.

## Conflicts of interest

There are no conflicts of interest.

## REFERENCES

1. Rothermund JL, Rabe AJ, Zumberge NA, Murakami JW, Warren PS, Hogan MJ. Image-guided percutaneous removal of ballistic foreign bodies secondary to air gun injuries. *Pediatr Radiol* 2018;48:120-3.
2. Nooghabi AM, Hassanpour MM, Jangjoo AM. Consequences of lost gallstones during laparoscopic cholecystectomy: A review article. *Surg Laparosc Endosc Percutan Tech* 2016;26:183-92.
3. Alexander HC, Bartlett AS, Wells CI, Hannam JA, Moore MR, Poole GH, *et al.* Reporting of complications after laparoscopic cholecystectomy: A systematic review. *HPB (Oxford)* 2018;20:786-94.

4. Trerotola SO, Lillemoe KD, Malloy PC, Osterman FA Jr. Percutaneous removal of “dropped” gallstones after laparoscopic cholecystectomy. *Radiology* 1993;188:419-21.
5. Zamir G, Lyass S, Pertsemliadis D, Katz B. The fate of the dropped gallstones during laparoscopic cholecystectomy. *Surg Endosc* 1999;13:68-70.
6. Hornof R, Pernegger C, Wenzl S, Bittermann G, Brinninger G, Tessadri R, *et al.* Intraoperative cholelithiasis after laparoscopic cholecystectomy--behavior of “lost” concretions and their role in abscess formation. *Eur Surg Res* 1996;28:179-89.
7. Roberts DJ, Chun HM. Dropped gallstone as a nidus of intra-abdominal abscess complicated by empyema. *Clin Infect Dis* 2005;41:e64-6.
8. Jaunoo SS, Mohandas S, Almond LM. Postcholecystectomy syndrome (PCS). *Int J Surg* 2010;8:15-7.
9. Girometti R, Brondani G, Cereser L, Como G, Del Pin M, Bazzocchi M, *et al.* Post-cholecystectomy syndrome: Spectrum of biliary findings at magnetic resonance cholangiopancreatography. *Br J Radiol* 2010;83:351-61.
10. Lamberts MP, Den Ouden BL, Gerritsen JJ, Roukema JA, Westert GP, Drenth JP, *et al.* Prospective multicentre cohort study of patient-reported outcomes after cholecystectomy for uncomplicated symptomatic cholelithiasis. *Br J Surg* 2015;102:1402-9.
11. de'Angelis N, Catena F, Memeo R, Coccolini F, Martínez-Pérez A, Romeo OM, *et al.* WSES guidelines for the detection and management of bile duct injury during cholecystectomy. *World J Emerg Surg* 2021;16:30.

**How to cite this article:** Chivi SP, Carbonella G. Percutaneous CT-guided retrieval of a retained gallstone to treat a cutaneous fistula following cholecystectomy. *Am J Interv Radiol* 2022;6:10.

