



## Vascular Interventions Case Report

# Transcarotid artery revascularization of a symptomatic carotid artery with a tortuous intrathoracic component

Dakota Gonring<sup>1</sup>, Mohammad Rachad Wehbe<sup>1</sup>, Michael Stoner<sup>1</sup>, Doran Mix<sup>1</sup>

<sup>1</sup>University of Rochester Medical Center, Department of Surgery, Division of Vascular Surgery, Rochester, New York, United States.



### \*Corresponding author:

Doran Mix, MD,  
Division of Vascular Surgery,  
Rochester, New York, United States.

[dmix@urmc.rochester.edu](mailto:dmix@urmc.rochester.edu)

Received : 03 March 2023

Accepted : 30 March 2023

Published : 12 April 2023

### DOI

10.25259/AJIR\_14\_2023

### Quick Response Code:



## ABSTRACT

We present the case of a tortuous intrathoracic common carotid artery (CCA) with a symptomatic right internal carotid artery lesion. This patient had a complex medical history, including a previous intraoperative cardiac arrest during attempted carotid endarterectomy (CEA) initially attributed to heparin anaphylaxis. She received maximum medical management but presented 6 months later to our institution with a secondary transient ischemic attack. Surgical options for the case were discussed amongst a multidisciplinary team. Transfemoral and transradial stenting were deemed non-viable due to the tortuous nature of the CCA. Repeat CEA under general anesthesia was deemed risk-prohibitive from a cardiac risk perspective. For these reasons, the patient was offered transcarotid artery revascularization (TCAR) under regional anesthesia. Intraoperatively, the “sheath stopper” was removed from the TCAR device, allowing the sheath to be advanced to 6 cm, effectively removing the tortuous component of the CCA. Flow reversal was established, and the operation proceeded in the standard fashion without neurologic change. The patient has remained on dual antiplatelet therapy and completed 2-year follow-up without evidence of restenosis, access site complication, or repeat neurologic event. This case demonstrates the potential applicability of TCAR to benefit a subset of patients who previously lacked a surgical option due to anatomical constraints.

**Keywords:** Arterial tortuosity, Carotid stenosis, Carotid stent, Stroke, Transcarotid artery revascularization

## INTRODUCTION

Transcarotid artery revascularization (TCAR) has emerged as a promising method for revascularizing the internal carotid artery (ICA). TCAR offers greater neurovascular embolic protection than carotid artery stenting (CAS) and is less invasive than carotid endarterectomy (CEA) – the gold standard for surgical treatment of ICA stenosis. Historically, we have not known how TCAR compares with CEA, but our understanding is changing as more data becomes available. One recent study found that TCAR compares favorably to CEA in octogenarians when considering stroke risk and mortality up to one year after surgery.<sup>[1]</sup> We found that our patient – an 84-year-old woman with a previous cardiac arrest during aborted right CEA and tortuous common carotid arteries (CCAs) – also benefited from TCAR because it gave direct surgical access to her CCA, a unique feature of this endovascular technique.

## CASE REPORT

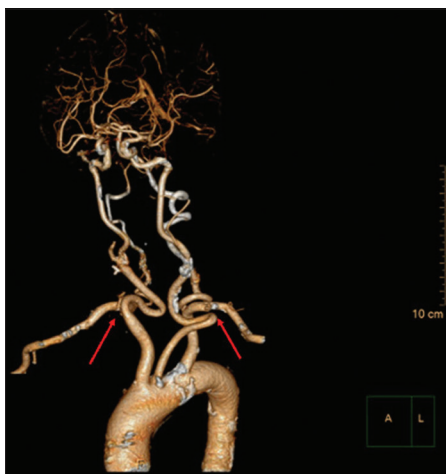An 84-year-old female with a complex medical history, including prior coronary stent placement followed by 5-vessel coronary artery bypass surgery, presented with the left arm and leg

This is an open-access article distributed under the terms of the Creative Commons Attribution-Non Commercial-Share Alike 4.0 License, which allows others to remix, transform, and build upon the work non-commercially, as long as the author is credited and the new creations are licensed under the identical terms.

©2023 Published by Scientific Scholar on behalf of American Journal of Interventional Radiology

weakness. Magnetic resonance imaging demonstrated acute infarction in the parietal-occipital region, while computed tomography angiography (CTA) showed >50% calcified stenosis of the bilateral ICAs. She was initially treated with tissue plasminogen activator and placed on dual anti-platelet therapy along with a high-intensity statin. Vascular surgery was consulted for definitive treatment of her right ICA lesion, and it was determined that CEA was the best method for revascularization. Unfortunately, her CEA had to be aborted intraoperatively because she developed pulseless electrical activity (PEA) following heparin administration requiring cardiopulmonary resuscitation. The etiology of her cardiac arrest was unknown but initially attributed to heparin anaphylaxis. She recovered after a brief hospital stay and was discharged on maximum medical therapy.

Five months later, she was referred to our clinic for second opinion of TCAR. Considering her high-risk surgical status and atypical anatomy, further surgical intervention was deferred in favor of continued medical management. Unfortunately, 1 month later, she presented with recurrent transient ischemic attack symptoms due to the right anterofrontal lobe and left hemispheric lesions. On computed tomography (CT), her right carotid artery plaque had high-risk morphology, placing her at risk for ipsilateral stroke without surgery. A CTA of the neck showed tortuous bilateral CCAs [Figure 1], complicating an endovascular approach. Reoperative CEA under general anesthesia was excluded as an option given her intraoperative PEA arrest 7 months prior.



**Figure 1:** An 84-year-old woman who presented with the left arm and leg weakness diagnosed with the right anterofrontal lobe and left hemispheric lesions secondary to internal carotid artery stenosis. Bilateral tortuous common carotid arteries were demonstrated on computed tomography angiography during surgical planning and later with 3D reconstruction, seen above.

A multidisciplinary team evaluated her for further risk stratification. Echocardiography showed preserved ejection fraction and multiple wall motion abnormalities consistent with her prior myocardial infarction; EKG and nuclear stress testing did not show evidence of new ischemia. Cardiology determined that her prior episode of cardiac arrest was associated with 15 s of asystole followed by junctional and ventricular escape beats, making the patient risk-prohibitive for general anesthesia. An allergist evaluated the patient for heparin anaphylaxis; she did not develop hives, angioedema, flushing, or ventilatory problems during heparin challenge, excluding heparin as a cause of her PEA. Repeat carotid Doppler imaging showed a right ICA peak systolic velocity of 190 cm/s and end diastolic velocity of 40 cm/s, a slight increase from prior with antegrade flow in the right vertebral artery, right ICA/CCA ratio 2.28, left ICA/CCA 2.41 and patent bilateral vertebral arteries. In addition, she had a complete circle of Willis with a dominant left vertebral artery associated with mild atherosclerotic calcification on CT. The patient's risk factors were evaluated, and per the Vascular Surgery Group Cardiac Risk Index, she scored 6 with her preexisting risk factors (Age >80, CAD, long-term B-blockade use, and a history of coronary artery bypass graft), predicting a 6.6% risk of adverse cardiac outcome during carotid revascularization.<sup>[2]</sup> Her Wallaert life expectancy score was medium risk due to her status as an octogenarian, thus denoting an 80% 5-year survival.<sup>[3]</sup>

A final surgical approach was deliberated. Transfemoral and transradial CAS were discussed but believed to be non-viable given her tortuous right CCA. We concluded that the patient would be best served with an awake TCAR which would provide greater ability to push through the tortuous carotid, allow for better control of the sheath and provide neurovascular embolic protection. In addition, this approach allowed for neurologic monitoring with limited cardiac-risk under locoregional anesthesia.

We proceeded with TCAR under regional anesthesia with cervical plexus block. The procedure began with an incision between the heads of the sternocleidomastoid muscle. The common carotid artery (CCA) was dissected and looped with umbilical tape allowing some of the carotid redundancy to be pulled out of the surgical incision. The right CCA was accessed using the Seldinger technique, followed by the insertion of the standard TCAR microcatheter, allowing for angiographic definition of the bifurcation. The catheter and access wire were advanced to the bifurcation and replaced with a stiff Amplatz wire. Next, the "sheath stopper" which prevents the TCAR sheath from advancing more than 2.5 cm into the carotid artery, was removed, allowing the 8.5 French TCAR sheath to be advanced up to 12 cm into the artery. The sheath was advanced under fluoroscopy to ensure the dilator did not pass the carotid bifurcation. This step

removed the tortuous component of the carotid [Figure 2]. With the sheath beyond the intra-thoracic tortuous component, we proceeded with the regular TCAR operative steps after establishing flow reversal. The lesion was defined angiographically as 75% stenosis of the proximal ICA. Pre-stenting angioplasty with a 5 mm balloon was followed by deployment of an 8 mm × 40 mm Enroute stent (Silk Road Medical, Inc., Sunnyvale, CA). We waited for 2 min on continuous flow reversal after stent deployment before completion angiography was performed.

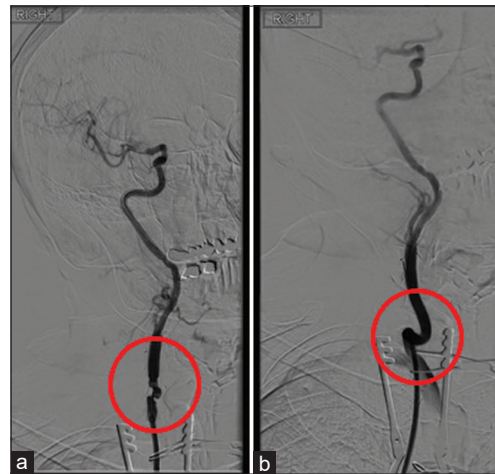
At the end of the case, cerebral angiography showed appropriate flow in the right anterior and middle cerebral arteries. We observed improved cross-hemispheric filling through the anterior communicating artery. The patient remained alert during the procedure without evidence of perioperative neurologic complications. She has completed 2-year follow-up without evidence of repeat neurologic event and routine duplex surveillance shows no evidence of post-operative in-stent stenosis or access-related complications.

## DISCUSSION

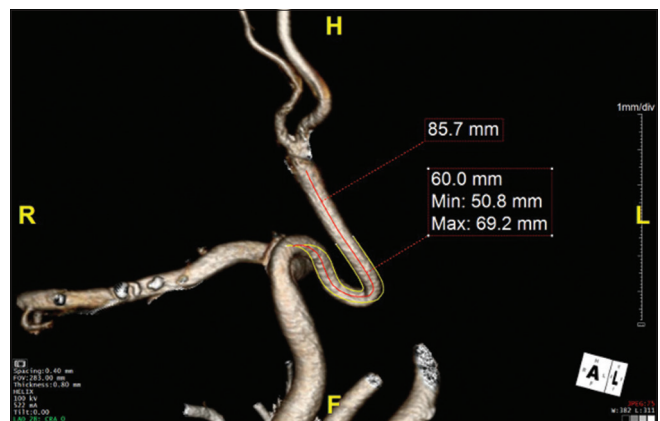
The patient's prior cardiac arrest during her initial CEA made her risk-prohibitive for reoperative CEA. Anatomy was the major obstacle to revascularizing her ICA endovascularly. The intra-thoracic portion of her CCA tortuosity measured 6 cm [Figure 3], which would have made it challenging to maneuver from transfemoral or trans-radial access. This patient also had complex medical factors, including prior multivessel CABG and concern for heparin-associated anaphylaxis, a rarely documented phenomenon.<sup>[4]</sup> A multidisciplinary team determined that she was not allergic to heparin, but her prior cardiac arrest made her risk-prohibitive for general anesthesia. For these reasons, and due to the author's surgical expertise with direct transcervical carotid access, a TCAR with loco-regional anesthesia was chosen to revascularize her ICA.

To successfully complete a TCAR in this case, patient-specific factors had to be considered. The instructions for use (IFU) criteria for the Enroute transcrotid neuroprotection system recommend greater than a 5 cm distance between the CCA access site and the carotid bifurcation.<sup>[5]</sup> The patient in our case had 3.9 cm separating her clavicle from her carotid bifurcation, making her a poor candidate. If she had been allergic to heparin, TCAR would have been contraindicated per the Enroute IFU, but notably, our center has completed the procedure using bivalirudin as a heparin alternative. The short, 3.9-cm distance to her bifurcation and the long intra-thoracic length of her CCA tortuosity necessitated that we advance the sheath without the "sheath stopper" to the full 6 cm distance intraoperatively. This maneuver allowed us to straighten her CCA and stent her ICA lesion.

We could not identify literature related to tortuous carotid traversal for TCAR with Enroute system-use to date of this procedure. In patients with typical anatomy undergoing TCAR, stabilization of the CCA for micropuncture can be achieved with mechanical traction using an umbilical



**Figure 2:** An 84-year-old woman who presented with left arm and leg weakness diagnosed with the right anterofrontal lobe and left hemispheric lesions secondary to internal carotid artery stenosis. Bilateral tortuous common carotid arteries were demonstrated on computed tomography angiography during surgical planning. Intraoperative right oblique digital subtraction angiography showing the carotid artery following stent insertion with the sheath advanced to remove tortuosity (a) and the sheath retracted to allow the carotid to return its native conformation (b).



**Figure 3:** An 84-year-old woman who presented with left arm and leg weakness diagnosed with the right anterofrontal lobe and left hemispheric lesions secondary to internal carotid artery stenosis. Bilateral tortuous common carotid arteries were demonstrated on computed tomography angiography during surgical planning. Subtracted TeraRecon imaging revealed 6 cm intrathoracic common carotid artery tortuosity.

tape loop. When the sheath is advanced into the CCA, it is best controlled by placing counter-traction on the umbilical tape loop.<sup>[6]</sup> Several studies describe techniques for overcoming tortuous vasculature, but these fail to address the main anatomical challenge of crossing a tortuous CCA to revascularize a stenotic ICA.<sup>[7,8]</sup>

TCAR is associated with the lowest CAS 30-day stroke rates in high-risk patients.<sup>[6]</sup> Recent data showed no significant outcome difference between TCAR and CEA in octogenarians.<sup>[1]</sup> In addition, this study showed TCAR to be superior to transfemoral CAS in terms of stroke rate and composite outcomes of myocardial infarction and death. Finally, recent data would suggest that the number of intraprocedural cerebral embolic events, as detected by transcranial doppler, with TCAR rival that of CEA both with and without a shunt and remains significantly less than CAS with distal filter.<sup>[9]</sup>

## CONCLUSION

TCAR provides many benefits over other methods of revascularization. In this case, TCAR provided us with direct access to the patient's tortuous CCA. We found that advancing the Enroute sheath without the "sheath-stopper" into a tortuous CCA provided sufficient straightening for the completion of a TCAR. This is a rare disease presentation but demonstrates the applicability of TCAR to overcome complex anatomy and comorbid conditions.

## Declaration of patient consent

The authors certify that they have obtained all appropriate patient consent.

## Financial support and sponsorship

Nil.

## Conflicts of interest

There are no conflicts of interest.

## REFERENCES

1. Mehta A, Patel PB, Bajakian D, Schutzer R, Morrissey N, Malas M, *et al.* Transcarotid artery revascularization versus carotid endarterectomy and transfemoral stenting in octogenarians. *J Vasc Surg* 2021;74:1602-8.
2. Bertges DJ, Goodney PP, Zhao Y, Schanzer A, Nolan BW, Likosky DS, *et al.* The Vascular Study Group of New England Cardiac Risk Index (VSG-CRI) predicts cardiac complications more accurately than the Revised Cardiac Risk Index in vascular surgery patients. *J Vasc Surg* 2010;52:674-83, 683.e1-683.3.
3. Wallaert JB, Cronenwett JL, Bertges DJ, Schanzer A, Nolan BW, De Martino R, *et al.* Optimal selection of asymptomatic patients for carotid endarterectomy based on predicted 5-year survival. *J Vasc Surg* 2013;58:112-8.
4. Jayarangaiah A, Epperla N. Early recognition is the key to success: Pulseless electrical activity (PEA) as a manifestation of heparin-induced anaphylactoid reaction. *BMJ Case Rep* 2015;2015:bcr2015210828.
5. Wu WW, Liang P, O'Donnell TF, Swerdlow NJ, Li C, Wyers MC, *et al.* Anatomic eligibility for transcarotid artery revascularization and transfemoral carotid artery stenting. *J Vasc Surg* 2019;69:1452-60.
6. Malas MB, Leal J, Kashyap V, Cambria RP, Kwolek CJ, Criado E. Technical aspects of transcarotid artery revascularization using the ENROUTE transcarotid neuroprotection and stent system. *J Vasc Surg* 2017;65:916-20.
7. Zenteno MA, Santos-Franco JA, Moscote-Salazar LR, Lee A. Endovascular remodeling of tortuous cervical segments of the internal carotid artery that hinder the management of complex intracranial aneurysms. *Rom Neurosurg* 2013;20:257.
8. Cherian M, Mehta P, Poyyamoli S, Rahul K, Jenny G, Swamiappan E. Overcoming tortuous anatomy in intracranial intervention. *J Clin Intervent Radiol ISVIR* 2018;2:38-41.
9. Cekmecelioglu BT, Legeza P, Sinha K, Tekula P, Lumsden A, Garami Z. Preliminary experience with transcranial Doppler monitoring in patients undergoing carotid artery revascularization: Initial observations on cerebral embolization patterns. *J Vasc Ultrasound* 2021;45:104-10.

**How to cite this article:** Gonring D, Wehbe MR, Stoner M, Mix D. Transcarotid artery revascularization of a symptomatic carotid artery with a tortuous intrathoracic component. *Am J Interv Radiol* 2023;7:10.