

Vascular Interventions Case Report

Arteriovenous shunt status post-coronary artery bypass graft surgery treated with microcoil placement: A case report

Victoria Reick-Mitrisin¹, Jay Mohan², Justin Stenz³, Mark Zainea⁴

¹Department of Education, A.T. Still University-Kirkville College of Osteopathic Medicine, Kirkville, Missouri, Departments of ²Cardiology and ³Interventional Radiology, McLaren Macomb, Mount Clemens, ⁴Department of Cardiology, Cardiology Associates of Michigan, Roseville, Michigan, United States.



***Corresponding author:**

Victoria Reick-Mitrisin,
A.T. Still University-Kirkville
College of Osteopathic
Medicine, Liberty Township,
Ohio, United States.

sa202038@atsu.edu

Received : 22 September 2022

Accepted : 13 January 2023

Published : 16 February 2023

DOI

10.25259/AJIR_26_2022

Quick Response Code:



ABSTRACT

Accidental cardiac arteriovenous (AV) anastomoses is a rare but severe complication of coronary artery bypass grafting. This can result in high output heart failure if left untreated. Little research has been done on the mainstays of treatment for this condition. Our patient is an 82-year-old male with a history of known coronary artery disease, status post-coronary bypass grafting surgery, presented with increasing shortness of breath, which was initially determined clinically to be due to high output heart failure, which was later confirmed during cardiac catheterization procedure. Coronary cardiac catheterization was carried out 2 weeks prior at an outside hospital for which the graft, which is supposed to be anastomosed of the circumflex, inadvertently anastomosed to the coronary sinus. The patient returned to the cardiac catheter lab and repeat angiography was performed. The left to right shunt was subsequently embolized using microcoils. He tolerated the procedure well. No recurrent anginal and/or heart failure symptoms were present. Interventional cardiology began the procedure by gaining right common femoral access. Next the saphenous vein graft to the coronary sinus was engaged with a 6 French JRy (Medtronic Inc., Minneapolis, MN) guide catheter and a 0.014" coronary wire was placed into the graft. Then interventional radiology advanced a 2.4 French microcatheter (Terumo, Ann Arbor, MI USA) over the 0.014" wire (Abbott Vascular Devices, Plymouth MN) into the mid to distal aspect of the bypass graft. Four detachable 0.018" microcoils (Terumo, Ann Arbor, MI USA) were carefully placed within the bypass graft. Subsequent angiogram demonstrated complete occlusion of the bypass graft with resolution of the AV shunt. Due to the acuity of the patient's symptoms and the long timeframe from originally attempting stenting, no additional attempts to stent the circumflex were performed. Follow-up angiogram through the base catheter demonstrates complete occlusion of the bypass graft with resolution of the AV shunt. No contrast was seen entering the coronary sinus. The patient tolerated the procedure well with no immediate complications. Estimated blood loss was <10 mL. The patient was admitted overnight for further evaluation. No shortness of breath noted. He was discharged in good condition the following day. Accidental cardiac AV anastomosis is a rare complication of coronary artery bypass grafting that could lead to high output heart failure. In such cases, catheter directed embolization with microcoils can be done to occlude the AV shunt created by the previously placed cardiac catheter with resolution of heart failure symptoms.

Keywords: Coronary artery bypass graft, Arteriovenous shunt, Coil embolization, Multidisciplinary, Coronary artery embolization

INTRODUCTION

Inadvertent cardiac arteriovenous (AV) anastomoses are a rare and potentially severe complication of coronary artery bypass grafting surgery. This can result in high output heart failure if left

This is an open-access article distributed under the terms of the Creative Commons Attribution-Non Commercial-Share Alike 4.0 License, which allows others to remix, transform, and build upon the work non-commercially, as long as the author is credited and the new creations are licensed under the identical terms.

©2023 Published by Scientific Scholar on behalf of American Journal of Interventional Radiology

untreated. Little research has been done on the mainstays of treatment for this condition. This case report describes endovascular management of an inadvertent AV shunt through the coronary sinus. Successful occlusion of the coronary artery bypass graft was completed with coil embolization, leading to resolution of high output heart failure symptoms. This case demonstrates both the treatment of a rare condition and successful collaboration across multidisciplinary teams.

CASE REPORT

Our patient is an 82-year-old male with a history of known coronary artery disease, status post coronary bypass grafting surgery, presenting with increasing shortness of breath. He was found to have a left to right shunt causing high output heart failure by hemodynamic assessment [Figure 1]. Coronary angiography was performed 2 weeks prior at an outside hospital that demonstrated a saphenous vein graft, which was supposed to be anastomosed to the obtuse marginal branch of the circumflex, but instead was inadvertently anastomosed to the coronary sinus.

A multidisciplinary approach was taken with discussions between interventional cardiology, cardiothoracic surgery, and interventional radiology on the best treatment approach for the patient. The decision was made to treat the patient endovascular with the use of microcoils. Interventional cardiology began the procedure by gaining right common femoral access. Next the saphenous vein graft to the coronary sinus [Figure 2]

engaged with a 6 French JRy (Medtronic Inc., Minneapolis, MN) guide catheter and a 0.014" coronary wire was placed into the graft. Then interventional radiology advanced a 2.4 French microcatheter (Terumo, Ann Arbor, MI USA) over the 0.014" wire (Abbott Vascular Devices, Plymouth MN) into the mid to distal aspect of the bypass graft. Four detachable 0.018" microcoils (Terumo, Ann Arbor, MI USA) were carefully placed within the bypass graft. Subsequent angiogram demonstrated complete occlusion of the bypass graft with resolution of the AV shunt. No contrast was seen entering the coronary sinus. Hemodynamic assessment confirmed resolution of the shunt. The patient tolerated the procedure well with no immediate complications. Estimated blood loss was <10 mL. The patient was admitted overnight for further evaluation. No shortness of breath noted. He was discharged in good condition the following day. Left ventricular systolic function improved to 50% status post procedure.

DISCUSSION

The incidence of coronary AV fistulas is between 0.2% and 2%, with most cases being congenital. As the patient increases in age, they are more likely to have complications. Our case is unique in that the cause of the AV shunt is iatrogenic rather than congenital in origin, rarely previously reported in the literature.^[3] Although rarely procedurally related, proper diagnosis and treatment of AV coronary shunts are critical, as the long-term complications can be

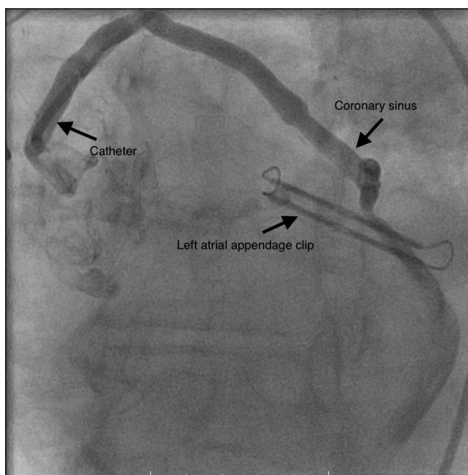


Figure 1: A 82-year-old male presenting with increasing shortness of breath and was subsequently found to have high output heart failure. Contrast-enhanced fluoroscopic imaging of the patients coronary vasculature demonstrated a saphenous vein graft, which is supposed to be anastomosed to the obtuse marginal branch of the circumflex, was inadvertently anastomosed to the coronary sinus. Catheter and successfully placed coils depicted above with black arrow.

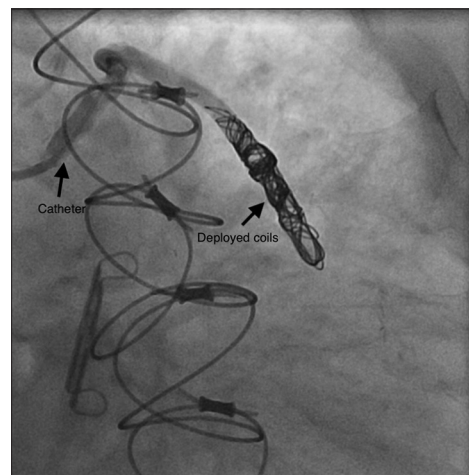


Figure 2: A 82-year-old male presenting with increasing shortness of breath and was subsequently found to have high output heart failure. Contrast-enhanced fluoroscopic imaging of the patients coronary vasculature demonstrated successful occlusion of the coronary arteriovenous shunt status post microcoil placement. Catheter and successfully placed coils depicted above with black arrow.

significant and potentially irreversible. It is important to note that the successful treatment of this rare condition was achieved using a multidisciplinary approach. There is currently little literature present on the successful reversal of AV shunts due to iatrogenic injury, and even less about the use of multidisciplinary teams in the operating room. The most common complication being the “coronary steal” phenomenon, which occurs due to the shunting of blood from a high-pressure part of the circulatory system to the lower pressure vessels in the pulmonary vasculature.^[3] Historically, coronary artery fistulas were evaluated with conventional invasive angiography but computed tomographic angiography is now the recommended option due to the short acquisition time and high spatial and temporal resolution.^[4] A low clinical suspicion to perform this procedure is important due to the potential long-term sequelae if left untreated.

There are a variety of treatment options for coronary AV shunts outlined in the literature, including the transcatheter approach as described in our patient, surgical treatment, and pharmacotherapy to reduce heart failure symptoms.^[3] While asymptomatic cases do not require immediate treatment, more severe cases could lead significant and irreversible consequences.^[3] Catheter directed embolization is the gold standard due to its low complication rate and higher efficacy compared to surgical or medical management. However, vessel tortuosity and lumen size limit the ability to perform this in certain patients.^[5] When reasonable an endovascular approach should be considered because the rate of recurrence with catheter embolization is 9–19% compared to surgical management with a 25% rate of recurrence.^[6]

There has been an uptick in use of the endovascular catheter approach, due to the advancement in procedural equipment available. With little literature detailing a successful treatment strategy in iatrogenic cases, early documentation of a successful multidisciplinary approach is useful to consider for future cases. This is important to determine the best method of embolization (plug vs. coil) due to the complex cardiac vascular anatomy and potential risks for post-procedural complications. Controlled release coils have been shown to have significantly contributed to catheter-based method of embolization and control of perforations in the coronary arteries, with one study reporting successful occlusion in 97% of patients.^[7] Covered stents have been shown to be efficacious in the treatment of cardiac shunts and in the reduction of reflow rate. In addition, these shunts may concomitantly exist with pseudoaneurysm. The presence of a pseudoaneurysm may further alter the treatment of the patient. It is important to take a multidisciplinary approach to patient management as these cases are rare and individual anatomy and shunt location can alter treatment strategies.^[8] Further research should be directed towards finding ways to increase use of this treatment modality in a larger patient population due to the less invasive nature of the procedure and high success rate.^[9]

CONCLUSION

Inadvertent cardiac AV anastomosis is a rare complication of coronary artery bypass grafting that can lead to high output heart failure. As shown in our case, an endovascular approach with microcoils is a viable treatment strategy to occlude an AV shunt due to iatrogenic injury from a previous intervention using catheter-directed embolization.^[1,2]

Acknowledgments

Thank you, Dr. Mohan and Dr. Stenz, for your procedural efforts and work with advising and manuscript coaching. Thank you, Dr. Zainea, for your incredible work following and caring for this patient. All your efforts on this unique case led to exceptional patient outcomes.

Declaration of patient consent

Patient's consent not required as patients identity is not disclosed or compromised.

Financial support and sponsorship

Nil.

Conflicts of interest

There are no conflict of interest.

REFERENCES

- Armsby LR, Keane JF, Sherwood MC, Forbess JM, Perry SB, Lock JE. Management of coronary artery fistulae. Patient selection and results of transcatheter closure. *J Am Coll Cardiol* 2002;39:1026-32.
- Perry SB, Rome J, Keane JF, Baim DS, Lock JE. Transcatheter closure of coronary artery fistulas. *J Am Coll Cardiol* 1992;20:205-9.
- Challoumas D, Pericleous A, Dimitrakaki IA, Danelatos C, Dimitrakakis G. Coronary arteriovenous fistulae: A review. *Int J Angiol* 2014;23:1-10.
- Yun G, Nam TH, Chun EJ. Coronary artery fistulas: Pathophysiology, imaging findings, and management-erratum. *Radiographics* 2018;38:2214.
- Collins N, Mehta R, Benson L, Horlick E. Percutaneous coronary artery fistula closure in adults: Technical and procedural aspects. *Catheter Cardiovasc Interv* 2007;69:872-80.
- Said SA, Nijhuis RL, Op den Akker JW, Kimman GP, Van Houwelingen KG, Gerrits D, *et al.* Diagnostic and therapeutic approach of congenital solitary coronary artery fistulas in adults: Dutch case series and review of literature. *Neth Heart J* 2011;19:183-91.
- Qureshi SA, Tynan M. Catheter closure of coronary artery fistulas. *J Interv Cardiol* 2001;14:299-307.
- Barekatin A, Fanari Z, Weiss SA. Aortocoronary saphenous vein graft aneurysm with fistula to the right atrium: Percutaneous management of surgical complication. *Del Med*

J 2015;87:370-5.

9. Reidy JF, Anjos RT, Qureshi SA, Baker EJ, Tynan MJ. Transcatheter embolization in the treatment of coronary artery fistulas. *J Am Coll Cardiol* 1991;18:187-92.

How to cite this article: Reick-Mitrisin V, Mohan J, Stenz J, Zainea M. Arteriovenous shunt status post-coronary artery bypass graft surgery treated with microcoil placement: A case report. *Am J Interv Radiol* 2023;7:5.