



Technical Innovation

Application of the gunsight technique to facilitate subintimal arterial flossing with antegrade-retrograde intervention for the treatment of lower extremity chronic total occlusion

Daniel Rohan Phadke¹, Daniel Sheeran¹, John Angle¹, Luke Wilkins¹

¹Department of Vascular and Interventional Radiology, University of Virginia, Charlottesville, Virginia, United States.



*Corresponding author:
Daniel Rohan Phadke,
Department of Vascular and
Interventional Radiology,
University of Virginia,
Charlottesville, Virginia,
United States.

drp4cf@virginia.edu

Received : 02 July 2020
Accepted : 15 September 2020
Published : 12 October 2020

DOI
10.25259/AJIR_15_2020

Quick Response Code:



ABSTRACT

Objectives: Endovascular treatment of atheromatous chronic total occlusions (CTOs) of the lower extremity using the subintimal arterial flossing with antegrade-retrograde intervention (SAFARI) method may fail due to inability to position the antegrade and retrograde wires in the same plane. Failed attempted SAFARI in three limbs, in two patients, was rescued using a gunsight technique.

Material and Methods: Retrospective procedure database review revealed three procedures where an occlusion could not be crossed despite antegrade and retrograde access which were treated using a novel technique for percutaneous puncture through antegrade and retrograde loop snares (gunsight technique).

Results: Three limbs in two patients (mean age: 64 years) were treated using the gunsight technique. All three CTOs were successfully crossed and dilated with angioplasty and/or stents. A positive clinical outcome was achieved in each of the three affected limbs.

Conclusion: The gunsight technique can improve technical success of SAFARI in the treatment of CTOs for atheroocclusive disease when there is failure to cross the lesion with standard endoluminal or subintimal approaches.

Keywords: Arterial intervention, Chronic total occlusions, Gunsight technique, Subintimal arterial flossing with antegrade-retrograde intervention

INTRODUCTION

Endovascular revascularization has been demonstrated to be an effective therapy for patients with chronic critical limb ischemia (CCLI).^[1,2] Chronic total occlusions (CTOs) of infrainguinal arteries are present in approximately 50% of patients who undergo endovascular treatment of CCLI or claudication with lifestyle limitation.^[3] Endovascular crossing of peripheral CTOs or near total occlusions is a significant barrier to effective limb revascularization. As a result, various methods have been developed to facilitate crossing diseased arterial segments when an intraluminal approach fails. The initial description of arterial recanalization through the subintimal plane was first described by Bolia *et al.* for the treatment of long superficial femoral artery (SFA) and tibial occlusions.^[4,5] Since its original description, subintimal angioplasty has proven

This is an open-access article distributed under the terms of the Creative Commons Attribution-Non Commercial-Share Alike 4.0 License, which allows others to remix, tweak, and build upon the work non-commercially, as long as the author is credited and the new creations are licensed under the identical terms.

©2020 Published by Scientific Scholar on behalf of American Journal of Interventional Radiology

to be an effective alternative to surgical bypass in patients with atheroocclusive disease of the SFA.^[2] Subintimal arterial flossing with antegrade-retrograde intervention (SAFARI) is a technique to improve technical success when performing subintimal recanalization if there is failure to reenter the distal true lumen.^[6,7] This involves additional retrograde wire access in the distal target artery to create a retrograde subintimal channel. A guidewire is used to connect the antegrade and retrograde subintimal channels to achieve through and through access. However, if this approach fails, the gunsight technique can be utilized to augment technical success. In this report, we present three limbs in two patients in whom lower extremity endovascular intervention in an unsuccessful SAFARI was salvaged using a novel application of a percutaneous puncture through loop snares (gunsight technique).

MATERIAL AND METHODS

One lower extremity of a male patient (64 years) with CTO of the left anterior tibial artery diagnosed on CTA with runoff and bilateral lower extremities of one female (64 years) with CTOs of bilateral SFAs diagnosed on lower extremity angiography were treated with SAFARI assisted by the gunsight technique in 2019.

Case report and technical description

Case 1

A 64-year-old male with a history of CVA, uncontrolled Type 2 diabetes, hypertension, and atrial fibrillation presented with a 1-month history of discoloration of the left 2nd and 5th pedal digits and several days history of the left foot pain at rest. The left lower extremity angiography demonstrated chronic occlusions of the anterior and posterior tibial arteries with single vessel runoff to the foot through the peroneal artery. There was collateral reconstitution of the dorsalis pedis artery [Figure 1a].

After diagnostic imaging, the sheath was upsized and advanced into the SFA. Antegrade crossing was unsuccessful. Retrograde access was established with puncture of the left distal anterior tibial artery. A 300 cm Nitrex wire (Medtronic, Dublin, Ireland) and 150 cm CXI catheter (Cook Medical, Bloomington, IN) were advanced to the proximal AT. Attempts to connect the subintimal tracts were unsuccessful. Two 4 mm 175 cm Ev3 microsnare (Medtronic, Dublin, Ireland) were advanced from the antegrade and the retrograde accesses. The loop snares were aligned at the same craniocaudal level, and the C-arm was rotated to align the loop snares in the same plane (gunsight technique). Then, a 21G micropuncture needle was advanced through both snares. Once the intrasnare location was confirmed with rotational fluoroscopy, a Regalia 300 cm 0.014 in wire (Asahi

Intecc, Santa Ana, CA) was advanced through the needle and captured by the antegrade access snare [Figure 1b]. The floppy tip was captured and the snare and crossing catheter were pulled through the femoral sheath. To prevent trauma to below the knee vessels, the decision was made to also snare the floppy end of a wire from the inferior access. A 150 cm CXI was advanced over the up and over externalized wire from the right femoral access though the retrograde loop snare. The reversed regalia wire was replaced with a 300 cm 0.014 in command wire (Abbott, Chicago, IL) which was advanced through the femoral access, and the floppy end of the wire was then snared using the retrograde pedal access and pulled out through the access. The CXI was removed and the wire was clamped and through and through access from the right CFA to the left distal AT was achieved. The proximal to mid-AT was then sequentially angioplastied with 2 mm, 2.5 mm, and 3 mm balloons. The retrograde access was removed allowing additional angioplasty of the distal AT. Completion angiogram demonstrated brisk antegrade flow to the foot, no extravasation at the retrograde puncture site, and a small AV fistula [Figure 1c]. The peripheral pulses were audible on Doppler with improvement in the left DP pulse from pre-procedure.

Case 2

A 64-year-old female with a history of carotid artery stenosis, COPD, and hypertension presented with chronic bilateral rest pain in the feet and calf claudication at 100 feet. Previous intervention included aortobifemoral bypass graft. Angiography demonstrated an 18 cm occlusion of the proximal right SFA and 25 cm occlusion of the proximal left SFA with patent distal popliteal artery and runoff vessels bilaterally [Figure 2a]. Decision was made for staged endovascular recanalization of the bilateral SFA occlusions.

Right lower extremity intervention

A puncture was made in the aortobifemoral graft in the left groin. The aortic bifurcation was crossed with an 8.5 F Oscor steerable sheath with a 6 F sheath coaxially (Oscor, Palm Harbor, FL). The 6 F sheath was advanced into the right external iliac artery. Entrance to the SFA was probed with a 70 cm angled tip catheter (Cook Medical, Bloomington, IN) and a 150 cm Glidewire (Terumo, Shibuya, Japan), but the occluded segment could not be engaged. Retrograde access was obtained in the right posterior tibial artery. A 300 cm Nitrex wire was advanced into the posterior tibial artery. Using a 150 cm CXI catheter, a subintimal plane was entered in the region of the adductor hiatus. The subintimal plane was propagated proximally to the SFA stump. Reentry into the true lumen could not be achieved. Next, a 175 cm snare catheter was advanced from the left groin access, and a microsnare was also advanced

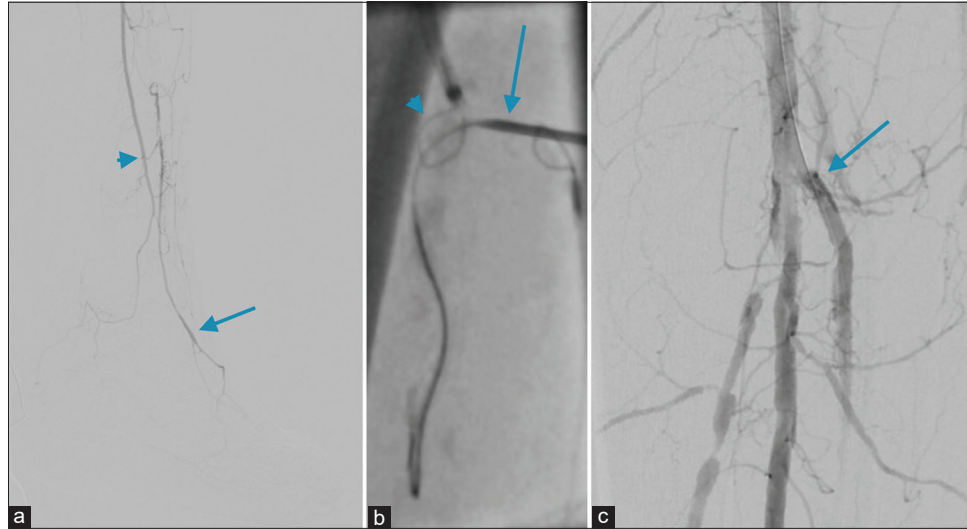


Figure 1: (a) A 64-year-old male patient presenting with distal left leg claudication. The left lower extremity angiography demonstrating collateral reconstitution of the dorsalis pedis artery (arrow) through the peroneal artery (arrow head). (b) The left lower extremity angiogram demonstrating the Regalia 300 cm 0.014 wire being advanced through micropuncture needle (arrow) and captured by the antegrade access snare (arrow head). (c) The left lower extremity angiogram demonstrating brisk antegrade flow to the foot and patent origin of the anterior tibial artery (arrow).

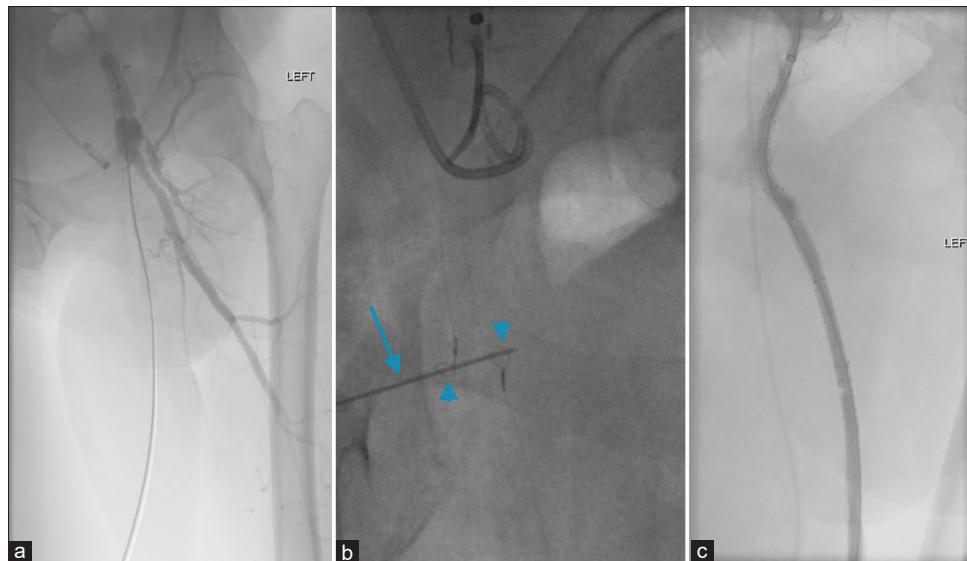


Figure 2: (a) A 64-year-old female patient with bilateral rest pain and calf claudication. Angiography of the left lower extremity demonstrating long-segment occlusion of the proximal left SFA. (b) The left lower extremity angiogram demonstrates the micropuncture needle (arrow) advanced through loop snares (arrow heads), and 0.018" wire advanced through the needle. (c) Completion angiogram demonstrating patent subintimal tract with exclusion of pseudoaneurysm.

from the right posterior tibial access. Puncture was made through both snares with a micropuncture needle. An 0.014 in command wire was advanced through the needle and pulled through the PT artery access. The back of the wire was snared and drawn through the left femoral access.

The subintimal tract was then dilated with a 4 mm balloon and then with 5 mm balloons. Due to elastic recoil, a 6 mm x 7.5 cm Viabahn stent (Gore Medical, Newark, DE) was placed. Repeat angiogram of the right common femoral artery demonstrated patency of the right SFA with no

extravasation. The sheaths were removed without difficulty and peripheral pulses were palpable.

Left lower extremity intervention

Retrograde access was obtained into the left brachial artery with a 21-gauge micropuncture set. Access site was chosen due to limitations from recent procedures and risk of retroperitoneal hemorrhage. A Glidewire and RIM catheter (Merit Medical, South Jordan, UT) were used to access the descending thoracic aorta. A 90 cm 6 Fr Raabe sheath (Cook Medical, Bloomington, IN) was advanced into the left common femoral artery. A Glidewire was used to create a subintimal tract at the level of the femoral neck. Retrograde access was created from the distal left dorsalis pedis artery. A Nitrex wire and CXI catheter were passed into the distal SFA, and a subintimal plane was entered to bypass the occluded SFA lumen. The wire was advanced to the level of the femoral neck, at the same level as the wire from the antegrade brachial access. The true lumen could not be accessed from the subintimal plane. A snare catheter was advanced from the left brachial access, and a separate snare was advanced from the left dorsalis pedis access. A micropuncture needle was advanced through the snares, and an 0.018" wire was advanced through the needle [Figure 2b]. The snare from DP access was used to pull the wire from the percutaneous access through the pedal access site and the snare from brachial access was then used to retract the trailing end of the wire through the brachial access to establish through and through access.

A CXI catheter was advanced along the wire from the brachial access, with significant difficulty crossing the point of access in the proximal left SFA due to the tortuosity of the tract. A sheath angiogram was performed and showed a pseudoaneurysm in the left groin. To cover the pseudoaneurysm, a 5 mm × 5 cm Viabahn stent was positioned across the left groin pseudoaneurysm. Follow-up angiogram showed persistent perfusion of the pseudoaneurysm.

Due to inability to advance additional stents into the subintimal tract or across the pseudoaneurysm, antegrade access was obtained in the left common femoral artery. The SFA stent was cannulated and a wire advanced into the anterior tibial artery. A 7 French 55 cm high flex Ansel sheath was advanced from the left CFA access into the distal SFA, and the subintimal tract was stented from distal to proximal with multiple overlapping covered stents. Stents were then post-dilated to 5 mm. Completion angiogram showed a patent subintimal tract with complete exclusion of the previously seen pseudoaneurysm [Figure 2c]. The sheaths were removed without difficulty and there were no immediate complications.

Follow-up

Patient 1 ultimately underwent left below the knee amputation due to continued poor wound healing of the

lower extremity wound. Before decision to amputate, the post-procedure pulse volume recording (PVR) and ankle brachial index (ABI) on post-procedure day 1 demonstrated incomputable ABI due to a non-compressible vessel, and monophasic Doppler waveforms noted on the left. However, a toe brachial index of 0.41 (previous 0.36) was noted in the left toe.

At 1-month follow-up for patient 2, the patient reported greatly improved walking ability without pain and no symptoms of rest pain. Peripheral vascular arterial duplex ultrasound and PVRs with ABIs demonstrated improvement from prior. Post-procedure ABIs were 0.71 (prior examination = 0.60) with monophasic Doppler waveform noted in the right leg at rest. Moderately abnormal ABI of 0.70 (prior examination = 0.53) with monophasic Doppler waveform was noted in the left leg at rest.

DISCUSSION

Subintimal recanalization is a key intervention for the treatment of CTO given the high technical success rate.^[8] The most difficult aspect of this method of recanalization is reentry into the true lumen distal to the diseased vessel segment. The SAFARI method serves to increase technical success in this regard and has proven to be an effective intervention for CTOs through the subintimal plane.^[6] If both wires are in the subintimal plane, a technique to increase technical success of connecting the antegrade and retrograde accesses includes the confluent balloon technique in which inflation of kissing antegrade and retrograde balloons creates one or more tears in the intima that allows communication between the two accesses.^[9] If one wire is in the true lumen and the other in the false lumen, the targeted reentry technique is a method that involves placement of a snare in the true lumen as a target for a reentry device in the false lumen.^[10] Another method to increase technical success of reentry to the true lumen is use of luminal reentry devices such as the Outback catheter. This is an angled guide catheter with an integral nitinol hypotube ending in a curved needle tip intended to be advanced from the end of the catheter to penetrate the true lumen from the dissection plane. The needle can be retracted into the guide catheter, and the device delivered over the wire to the point of true lumen reentry. Similarly, the OffRoad catheter is composed of a balloon catheter combined with a needle-tipped hypotube. The hypotube with a straight needle tip is advanced out of the balloon catheter end to penetrate the intima and plaque distal to the total occlusion to achieve true lumen reentry.

The percutaneous gunsight technique was originally described by Haskal *et al.* for use in complicated portosystemic shunt interventions.^[11] The technique involves aligning bidirectional loop snares as a target for puncture. A needle is placed percutaneously and sharp recanalization

is performed under fluoroscopic guidance using the bidirectional loop snares as a guide. A Glidewire is passed through the needle through both snares, the needle is then removed, and the retrograde snare pulls the wire down into the distal true lumen while the antegrade snare pulls the wire up into the proximal true lumen.

This method allows for revascularization when the antegrade and retrograde catheters are far from one another, an advantage over the SAFARI method alone. Kahn and Kaufman described successful application of a similar technique in the treatment of a popliteal artery CTO.^[12] The technique requires that loop snares can be at the same cranial-caudal level in the vessel. A potential risk of this technique is AV fistula formation given proximity of adjacent venous structures and potential communication. There is also the possibility of hemorrhage if an extravascular tract is created, requiring placement of a covered stent.

CONCLUSION

The gunsight technique increases chance of technical success in creating through and through access during SAFARI for the treatment of lower extremity CTO when there is a failure to cross the lesion with standard endoluminal or subintimal approaches. Further study and longer follow-up data are needed to draw significant conclusions regarding safety and efficacy.

Declaration of patient consent

The authors certify that they have obtained all appropriate patient consent.

Financial support and sponsorship

Nil.

Conflicts of interest

There are no conflicts of interest.

REFERENCES

1. Bradbury AW, Adam DJ, Bell J, Forbes JF, Fowkes FG, Gillespie I, *et al.* Multicentre randomised controlled trial of the clinical and cost-effectiveness of a bypass-surgery-first versus

a balloon-angioplasty-first revascularisation strategy for severe limb ischaemia due to infrainguinal disease. The bypass versus angioplasty in severe ischaemia of the leg (BASIL) trial. *Health Technol Assess* 2010;14:1-210.

2. Adam DJ, Beard JD, Cleveland T, Bell J, Bradbury AW, Forbes JF, *et al.* Bypass versus angioplasty in severe ischaemia of the leg (basil): Multicentre, randomised controlled trial. *Lancet* 2005;366:1925-34.
3. Nadal LL, Cynamon J, Lipsitz EC. Subintimal angioplasty for chronic total occlusions. *Tech Vasc Interv Radiol* 2004;7:16-22.
4. Bolia A, Brennan J, Bell PR. Recanalization of femoro-popliteal occlusions: Improving success by subintimal re-canalization. *Clin Radiol* 1989;4:325.
5. Bolia A, Sayer RD, Thompson MM, Bell PR. Subintimal and intraluminal re-canalization of occluded crural arteries by percutaneous balloon angioplasty. *Eur J Vasc Surg* 1994;8:214-9.
6. Spinosa DJ, Leung DA, Harthun NL, Cage DL, Angle JF, Hagspiel KD, *et al.* Simultaneous antegrade and retrograde access for subintimal recanalization of peripheral arterial occlusion. *J Vasc Interv Radiol* 2003;14:1449-54.
7. Spinosa DJ, Harthun NL, Bissonette EA, Cage D, Leung DA, Angle JF, *et al.* Subintimal arterial flossing with antegrade-retrograde intervention (SAFARI) for subintimal recanalization to treat chronic critical limb ischemia. *J Vasc Interv Radiol* 2005;16:37-44.
8. Bown MJ, Bolia A, Sutton AJ. Subintimal angioplasty: Meta-analytical evidence of clinical utility. *Eur J Vasc Endovasc Surg* 2009;38:323-37.
9. Ikushima I, Hirai T, Ishii A, Iryo Y, Yamashita Y. Confluent two-balloon technique: An alternative method for subintimal recanalization of peripheral arterial occlusion. *J Vasc Interv Radiol* 2011;22:1139-43.
10. Kitrou P, Parthipun A, Diamantopoulos A, Paraskevopoulos I, Karunanithy N, Katsanos K. Targeted true lumen re-entry with the outback catheter: Accuracy, success, and complications in 100 peripheral chronic total occlusions and systematic review of the literature. *J Endovasc Ther* 2015;22:538-45.
11. Haskal ZJ, Duszak R, Furth EE. Transjugular intrahepatic transcaval portosystemic shunt: the gun-sight approach. *J Vasc Interv Radiol* 1996;7:139-42.
12. Kahn SL, Kaufman JL. Extravascular revascularization of a chronic total occlusion using the dual bull's-eye technique. *J Endovasc Ther* 2016;23:903-6.

How to cite this article: Phadke DR, Sheeran D, Angle J, Wilkins L. Application of the gunsight technique to facilitate subintimal arterial flossing with antegrade-retrograde intervention for the treatment of lower extremity chronic total occlusion. *Am J Interv Radiol* 2020;4:12.