



Vascular Interventions Case Report

Endovascular retrieval of two migrated stents from pulmonary artery by means of balloon catheter

Saad Saeed Alqahtani¹, Ahmed Kandeel Elhadad¹, Rusha Abdulmohsen Sarhan¹, Saleh Mohamed Alwaleedi²

Departments of ¹Radiology and Medical Imaging and ²Cardiac Surgery, Armed Forces Hospital, Khamis Mushait, Saudi Arabia.



***Corresponding author:**

Saad Saeed Alqahtani,
Department of Radiology and
Medical Imaging, Armed Forces
Hospital, Khamis Mushait,
Saudi Arabia.

dr.salqahtani@gmail.com

Received : 17 July 2021

Accepted : 08 November 2021

Published : 24 November 2021

DOI

10.25259/AJIR_28_2021

Quick Response Code:



ABSTRACT

Long-term central venous catheters can be associated with central venous stenosis in up to 50% of cases. Central venous stenosis can be managed with central venous stenting which was demonstrated to restore patency and improve suboptimal results after percutaneous transluminal angioplasty. Dislodgment of venous stents into the right side of the heart or the pulmonary artery during stent deployment is one of the most feared complications of this procedure. Percutaneous removal of these migrated stents is the preferred alternative for the more invasive operative intervention, which may be very hazardous in these patients. We report an unusual case of a 52-year-old man on hemodialysis who underwent endovascular stenting to treat a tight stenosis of the right brachiocephalic vein and superior vena cava and suffered from stent migration to the left pulmonary artery, requiring removal by interventional radiologist.

Keywords: Case report, Stent migration and retrieval of stent, Superior vena cava angioplasty

INTRODUCTION

The main predisposing factor for central venous stenosis, a common complication of patients on hemodialysis, is the previous insertion of jugular or subclavian dialysis catheter, with an incidence rate as high as 50%.^[1] Treatment of subclavian vein stenosis aims to reduce the risk of thrombosis and improve upper extremity edema as well as improve hemodialysis pressure.^[2] Treatment for central venous stenosis includes percutaneous balloon angioplasty or stent deployment. Stenting is preferred than balloon angioplasty for central venous stenosis because angioplasty is usually associated with a high incidence of elastic recoil and restenosis.^[3] Stent migration can occur when used in large central veins leading to severe consequences such as pulmonary infarction, tricuspid regurgitation, and right side heart failure.^[4]

We report a case of 52-year-old patient with the right brachiocephalic and superior vena cava (SVC) stenosis treated with two over-balloon stents, which migrated to the left pulmonary artery, necessitating retrieval by interventional radiology.

CASE REPORT

A 52-year-old male patient with end-stage renal failure on maintenance hemodialysis through a right internal jugular permanent catheter developed progressive right arm and right facial swelling due to stenosis of the right brachiocephalic vein and proximal part of the SVC around the dialysis catheter. Accordingly, the patient was managed by removal of the catheter over a

This is an open-access article distributed under the terms of the Creative Commons Attribution-Non Commercial-Share Alike 4.0 License, which allows others to remix, tweak, and build upon the work non-commercially, as long as the author is credited and the new creations are licensed under the identical terms.

©2021 Published by Scientific Scholar on behalf of American Journal of Interventional Radiology

0.035 inch/180 cm angled Glidewire (Terumo Medical Corporation, Somerset, NJ, USA) followed by angioplasty using 10 mm × 60 mm balloon (Power Flex Cordis Corporation, Miami, FL, USA). This was followed by the insertion of two stents; a 12 mm × 40 mm self-expandable SMART stent (Cordis Corporation, Miami, FL, USA) and a 12 mm × 40 mm self-expandable fluency stent (C. R. Bard, Inc.; Tempe, AZ, USA) into the right brachiocephalic vein and proximal part of the SVC. A control venogram revealed restoration of good flow through the SVC [Figure 1]. During the introduction of the peel away sheath to facilitate the introduction of a new tunneled split catheter, the contact between the peel away sheath and the implanted stents at the superior margin of the SVC was associated with an instantaneous dislodgment of the stents. The two stents migrated, as one unit into the left pulmonary artery [Figure 2a].

Since the patient was asymptomatic and his vital signs were stable, no attempt was made to retrieve the migrated stent at this time. The patient was placed on full anticoagulation and transferred to the ward.

Twenty-four hours later, the patient was still asymptomatic and a control CT scan showed that the two stents are still located within the left pulmonary artery extending backward into the main pulmonary trunk [Figure 2b]. The case was discussed with the cardiothoracic surgeons and a decision was made to retrieve the stents to avoid the possibility of massive thrombosis and stent infection.

The patient was taken to the angiography suite and; through a percutaneous right femoral vein approach; a long 10F × 75 cm Mullins transseptal sheath (Cook Medical Inc.; Bloomington,

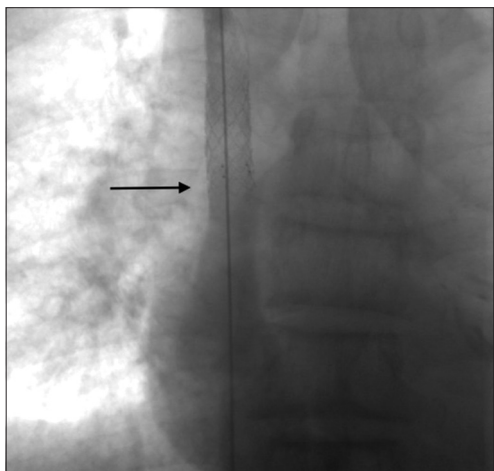


Figure 1: A 52-year-old patient with the right brachiocephalic and proximal superior vena cava (SVC) stenosis treated with two over-balloon stents, which migrated to the left pulmonary artery. Control venogram after stenting showing good flow of contrast through the deployed stents in the right brachiocephalic vein and the SVC (arrow) with no obvious stenosis.

Ind) was introduced over a 0.035/180 cm Terumo guide wire up to the junction of IVC and right atrium. A 5F cobra (C2) catheter was introduced over a J-shaped guidewire through the migrated stents then the wire was exchanged by a J-shaped 0.035 Amplatz Super Stiff wire (Boston Scientific/Scimed; Maple Grove, Minn). A 12 mm × 80 mm angioplasty balloon (Power Flex Cordis Corporation, Miami, FL, USA) was passed over the stiff guide wire into the migrated stents and was inflated to recapture the stents over the balloon [Figure 3a and b]. The balloon and the migrated stents were then carefully pulled out, all together, with the sheath down to the right common iliac vein where the stents were stuck and could not be pulled any more proximally. The stents were then inflated over the balloon in the right common and external iliac veins where they were left [Figure 4].

DISCUSSION

With the increasing number of central venous access procedures performed lately for oncology and renal impairment patients, the incidence of central venous stenosis/occlusion is becoming more prevalent. The postulated mechanisms involve turbulence, non-physiologic increase in flow volume, platelet aggregation, fibrosis, and stenosis of the lumen by central venous catheters.^[5]

Various interventional radiological procedures have evolved to treat central venous obstruction, such as balloon angioplasty, pharmacologic and mechanical thrombolysis, thrombectomy, and stenting. The frequent use of stenting as therapy for venous occlusion is controversial. Stenting is thought to act as an adjuvant to venous angioplasty by limiting the elastic recoil in non-compliant veins, excluding the damaged and dissected vasculature, and counteracting extrinsic compression.

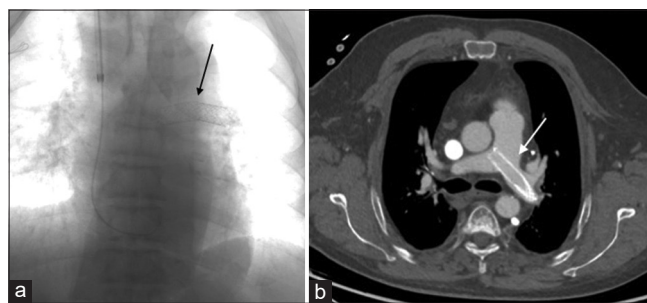


Figure 2: (a) A 52-year-old patient with the right brachiocephalic and proximal superior vena cava (SVC) stenosis treated with two over-balloon stents, which migrated to the left pulmonary artery. Fluoroscopy showing the dislodgement of the stents into the main pulmonary trunk and the left pulmonary artery (arrow). (b) A 52-year-old patient with the right brachiocephalic and upper SVC stenosis treated with two over-balloon stents, which migrated to the left pulmonary artery. Axial CT scan of the chest with contrast showing the migrated stents located in the main pulmonary trunk and the left pulmonary artery (arrow).

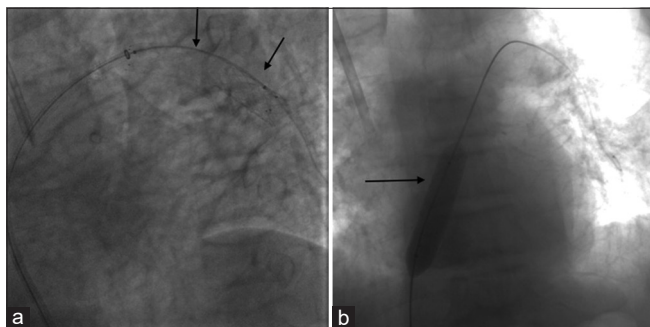


Figure 3: (a) A 52-year-old patient with the right brachiocephalic and upper superior vena cava (SVC) stenosis treated with two over-balloon stents, which migrated to the left pulmonary artery. Fluoroscopy showing the introduction of a 12 mm × 80 mm Power Flex angioplasty balloon over the Amplatz Stiff guide wire into the migrated stents (arrows). (b) A 52-year-old patient with the right brachiocephalic and upper SVC stenosis treated with two over-balloon stents, which migrated to the left pulmonary artery. Fluoroscopy showing the migrated stents after being captured over the inflated 12 mm × 80 mm Power Flex angioplasty balloon (arrow) and successfully pulled into the right atrium.

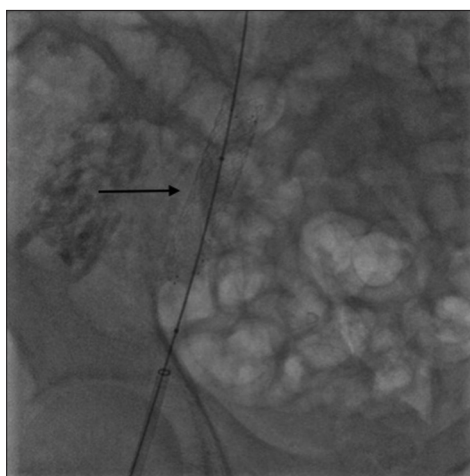


Figure 4: A 52-year-old patient with the right brachiocephalic and upper superior vena cava stenosis treated with two over-balloon stents, which migrated to the left pulmonary artery. Fluoroscopy of the right side of pelvis showing the two stents after being successfully inflated and deployed in the right common and external iliac veins (arrow) where they were left.

Complications of stent deployment include; recurrence of stenosis due to intimal hyperplasia, vessel perforation, misplacement, and migration. Migration is rare but it can be life threatening if the stent reaches the heart and pulmonary artery.^[6] Migration of stents to the right atrium, right ventricle,^[7] and pulmonary artery,^[8] after endovascular stenting for SVC syndrome has been reported previously. Predisposing factors for stent migration in the condition of SVC obstruction include (1) poor choice of lesion, (2) inadequate sizing of the stent, (3) inaccurate positioning of the stent, (4) effect of cardiac motion, (5) inaccurate vessel

measurement, (6) cases in which the disease is expected to be resolved with treatment, for example, Hodgkin's lymphoma, (7) stent deployment system, and (8) delivery route.^[9]

Selection of the correct stent size is a major determinant of the procedure success. The diameter of the stent must be greater than that of the designed vein to prevent stent migration. In our practice, when we deploy prosthesis in the arterial tree, the proper stent diameter must be 1–2 mm larger than the angiographically measured diameter of an adjacent proximal or contralateral artery. This oversizing must be doubled for veins, for which respiratory movements induce a great variability in the diameter. The stent length must be adapted to the length of the stenosis to cover the entire lesion. If necessary, two or more stents are placed in tandem; the cephalic stent must be placed first, followed by the caudal one. It is also important to place the stent across the center of the lesion to prevent milking of the stent by the stenosis with subsequent retraction and migration of the prosthesis. Pre-dilation of the pathologic vascular segment before deployment of the self-expanding stent was incriminated by some authors as promoting stent migration, particularly when the target vessel seems to be wide open. We believe that the radial force of most available self-expanding stents is adequate to expand a non-dilated vein; further, dilation may be considered to obtain optimal results.

Migrated stents must be removed to prevent further complications that include thrombosis, vessel trauma, and perforation. The migrated stents can be managed either by endovascular means or by open surgery. Taylor *et al.*^[9] described four different strategies for endovascular approaches of stent migration into the right atrium. These included: (1) Snaring the stent directly, (2) angioplasty balloon-assisted snaring of the stent, (3) guide wire-assisted snaring of the stent, and (4) superior vena cava-to-inferior vena cava bridging stent. The primary objective of percutaneous management is to remove the stent, but if removal is not possible or failed, the stent should be fixed by additional stent at an alternative intravascular location to prevent repeated movements of the stent, which may cause vascular injury.^[10] Success rates of percutaneous techniques in the management of migrated stents exceed 90%.^[10] Open surgical methods to retrieve migrated stents are associated with high morbidity.

Our case was unusual because the migrated stents were two in number and the migration occurred during the intervention procedure to treat SVC stenosis. Although the patient was asymptomatic, a decision was made to retrieve the stents to avoid potential complication such as thrombosis or perforation. The stents were retrieved over a balloon and were reimplemented within the right common and external iliac veins.

CONCLUSION

Stent migration is an infrequent complication of stenting of central venous system. Migrated stents should be retrieved even in asymptomatic patients to avoid serious complications. Retrieval could be done by endovascular interventional means.

Declaration of patient consent

Patient's consent not required as patients identity is not disclosed or compromised.

Financial support and sponsorship

Nil.

Conflicts of interest

There are no conflicts of interest.

REFERENCES

- Schillinger F, Schillinger D, Montagnac R, Milcent T. Post catheterisation vein stenosis in haemodialysis: Comparative angiographic study of 50 subclavian and 50 internal jugular accesses. *Nephrol Dial Transplant* 1991;6:722-4.
- NKF-DOQI clinical practice guidelines for hemodialysis adequacy. National kidney foundation. *Am J Kidney Dis* 1997;30:S15-66.
- Kovalik EC, Newman GE, Suhocki P, Knelson M, Schwab SJ. Correction of central venous stenoses: Use of angioplasty and vascular Wallstents. *Kidney Int* 1994;45:1177-81.
- Hoffere E, Mmaterne P, Desiron Q, Marenne F, Lecoq E, Boland J. Right ventricular migration of a venous stent: An unusual cause of tricuspid regurgitation and ventricular tachycardia. *Int J Cardiol* 2006;112:e48ee49.
- Maintz D, Landwehr P, Gawenda M, Lackner K. Failure of Wallstents in the subclavian vein due to stent damage. *Clin Imaging* 2001;25:133-7.
- Gray RJ, Dolmatch BL, Horton KM, Romolo JL, Zarate AR. Migration of Palmaz stents following deployment for venous stenoses related to hemodialysis access. *J Vasc Interv Radiol* 1994;5:117-20.
- Poludasu SS, Vladutiu P, Lazar J. Migration of an endovascular stent from superior vena cava to the right ventricular outflow tract in a patient with superior vena cava syndrome. *Angiology* 2008;59:114-6.
- Smayra T, Otal P, Chabbert V, Chemla P, Romero M, Joffre F, *et al.* Long-term results of endovascular stent placement in the superior caval venous system. *Cardiovasc Intervent Radiol* 2001;24:388-94.
- Taylor JD, Lehmann ED, Belli AM, Nicholson AA, Kessel D, Robertson IR, *et al.* Strategies for the management of SVC stent migration into the right atrium. *Cardiovasc Intervent Radiol* 2007;30:1003-9.
- Gabelmann A, Kramer S, Gorich J. Percutaneous retrieval of lost or misplaced intravascular objects. *AJR Am J Roentgenol* 2001;176:1509-13.

How to cite this article: Alqahtani SS, Elhadad AK, Sarhan RA, Alwaleedi SM. Endovascular retrieval of two migrated stents from pulmonary artery by means of balloon catheter. *Am J Interv Radiol* 2021;5:21.